Nephro Update Europe 2020

18 – 19 September, Amsterdam (Noordwijk)

KIDNEY DISEASE

Anti-neutrophil cytoplasmic antibody-associated vasculitis and/or polyarteritis nodosa: a case report of individual disease or overlap syndrome?

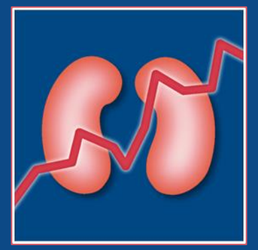

Borštnar Špela , Slovenia

Anti-neutrophil cytoplasmic antibody-associated vasculitis and/or polyarteritis nodosa: a case report of individual disease or overlap syndrome?

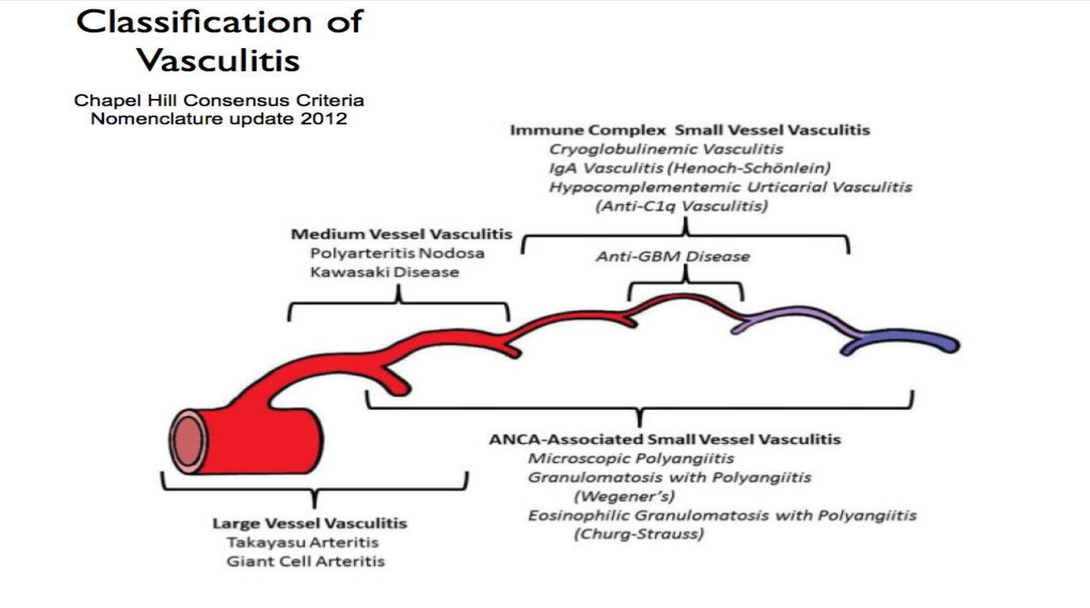

univerzitetni klinični center ljubljana
University Medical Centre Ljubljana

Borštnar Špela and Škoberne Andrej

Department of Nephrology, University Medical Center Ljubljana, Slovenia

Introduction: Polyarteritis nodosa (PAN) is a systemic necrotizing vasculitis that affects medium-sized and occasionally small arteries with development of aneurysms predominantly in abdominal organs, which can rupture and cause bleeding. Meanwhile anti-neutrophil cytoplasmic antibody (ANCA) associated small blood vessels vasculitis rarely causes life endangering abdominal haemorrhage. It is usually possible to distinguish these two diseases from each other.

A case report: A 65-year-old patient with:

- congestive heart failure with tachycardic atrial fibrillation, acute kidney injury (serum creatinine 254 µmol/L, proteinuria 2+ and haematuria 3+) and high CRP level (229 mg/L);
- general symptoms including malaise, cought and leg pain;
- a month ago, nasal mucosa biopsy (performed because of a “stuffy” nose) showed unspecified chronic suppurative inflammation;
- he was treated with beta blockers, digoxin, heparin, azithromycin and amoxicillin with clavulanic acid;
- on the 5th day: major abdominal bleeding (from the aneurysms of a. lienalis and a. hepatica confirmed with CT), with successful embolization;
- CRP level remained high, all microbiological results were negative, PR3 ANCA was 8 units/ml (slightly positive);
- renal function deteriorated, transiently he required haemodialysis.

Diagnostic dilemma: PAN and/or PR3 ANCA vasculitis (granulomatosis with polyangiitis)? Due to high risk of bleeding renal biopsy for final diagnosis setting was not performed.

PAN: renal artery angiography revealed small aneurysms in both kidneys, and aneurysms of spleen and liver.

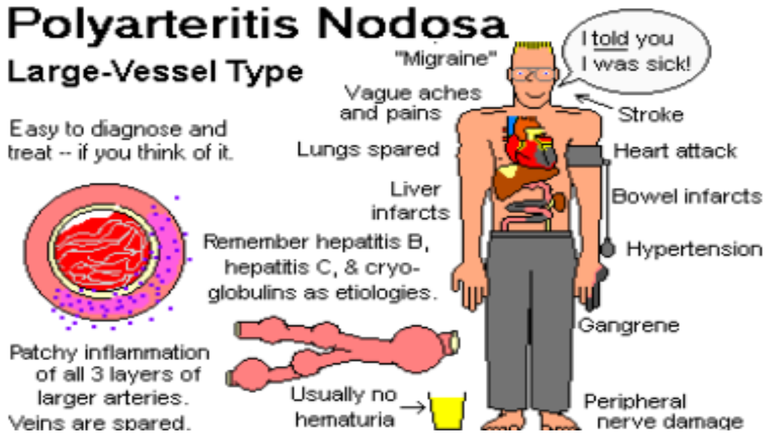

aneurysms in abdominal organs

PR3 ANCA vasculitis: nasal involvement and positive ANCA.

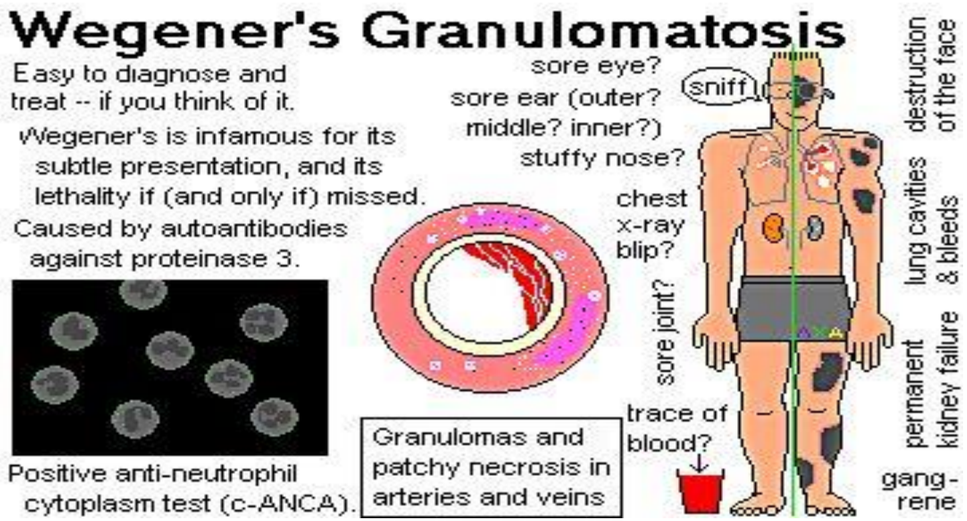

Induction treatment:

- methylprednisolone (3x 500mg i.v., 0.7 mg/kg oral);
- 1. pulse of cyclophosphamide 750 mg i.v., followed by next pulses separated by 4 weeks.

Outcome:

- renal function improved (s-creatinine 200 µmol/L);
- the general symptoms diminished;
- no bleeding any more.

Conclusion: We can conclude that the patient has convincing signs of PAN, however we cannot exclude possible overlap with ANCA positive vasculitis. Luckily the induction immunosuppressive treatment is similar in both diseases.

Literature:

1. Ullah, et al. Spontaneous retroperitoneal hematoma: a rare presentation of polyarteritis nodosa. J Investig Med High Impact Case Rep. 2019 Jan-Dec; 7: 2324709619858120.
2. Howard T, et al. Polyarteritis nodosa. Tech Vasc Interv Radiol. 2014; 17(4): 247-251.
3. Roberto M, et al. Ruptured hepatic aneurysm as first presenting symptom of polyarteritis nodosa. Oxford Medical Case reports. 2018; 2: 64-67.

Nephro Update Europe 2020
18 – 19 September, Amsterdam (Noordwijk)

OTHER

Combining Letermovir with Valganciclovir May Allow an Early Switch From Foscarnet Among Kidney-Transplant-Recipients With Ganciclovir-resistant CMV Infection

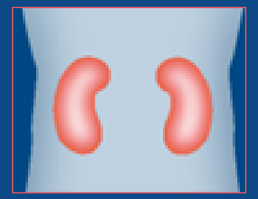

Elena Rho, Switzerland

USZ Universitäts Spital Zürich

Combining Letermovir with Valganciclovir May Allow an Early Switch From Foscarnet Among Kidney-Transplant-Recipients With Ganciclovir-resistant CMV Infection

Rho, E, MD,[1] Näf, B.[1], Müller, TF, MD, [1] Wüthrich, RP, MD, [1] Schachtner, T, MD[1], Von Moos S, MD[1]

[1] Division of Nephrology, University Hospital Zurich, Switzerland

USZ Universitäts Spital Zürich

Background: Ganciclovir (GCV) resistant cytomegalovirus (CMV) infection is a concerning condition in solid organ transplantation. Since treatment with foscarnet (FOS) is associated with nephrotoxicity, alternative treatments are required. Oral letermovir (LTV) might be a less toxic option. It has been approved for CMV prophylaxis, but its efficacy in treating active CMV infection is unclear.

Design: Retrospective, single-centre study (University Hospital Zürich)

Inclusion Criteria:

- Kidney transplant recipients (KTR) between 2009 - 2019
- GCV-resistant CMV infection

Treatment Regimens:

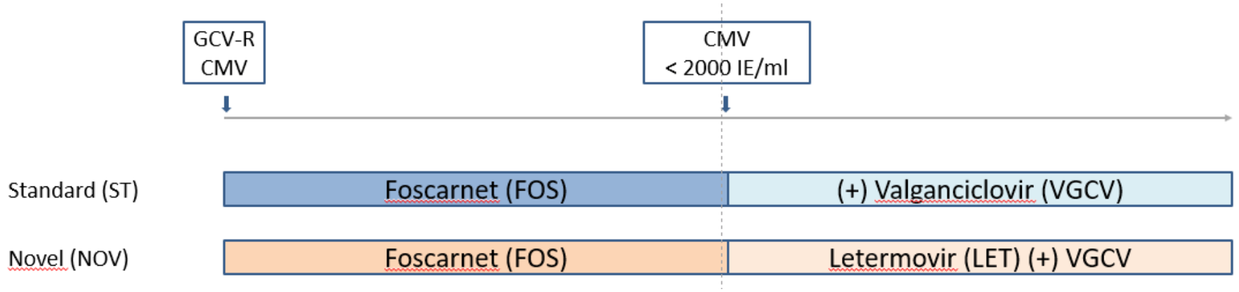

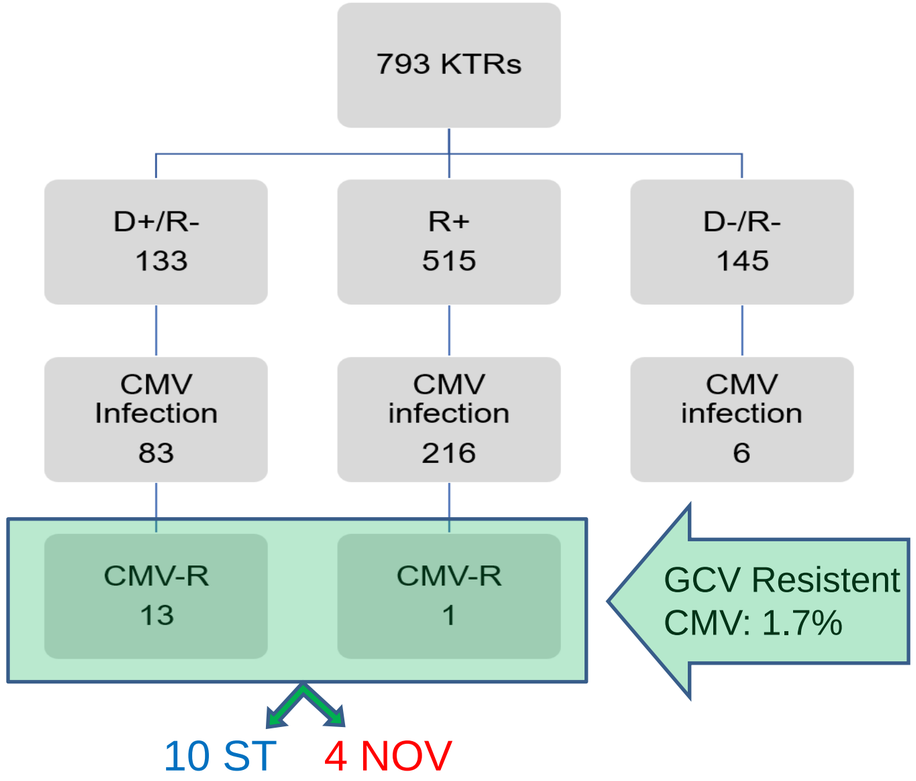

Outcome Data:

- Virus control (i.e. relapse of CMV viremia > 10’000 IE/ml)
- Patient outcome
- Renal outcome (i.e. kidney function)

USZ Universitäts Spital Zürich

Results:

Viral Relapse > 10’000 IE/ml

ST: (5/9): 56%

NOV: (1/4): 24%

Patient Survival:

ST: (x/x): 50%

NOV (4/4): 100%

Kidney Function:

Moderate Correlation FOS duration with kidney function deterioration (r=0.34, p=0.2).

Median days: ST 48 vs NOV 27

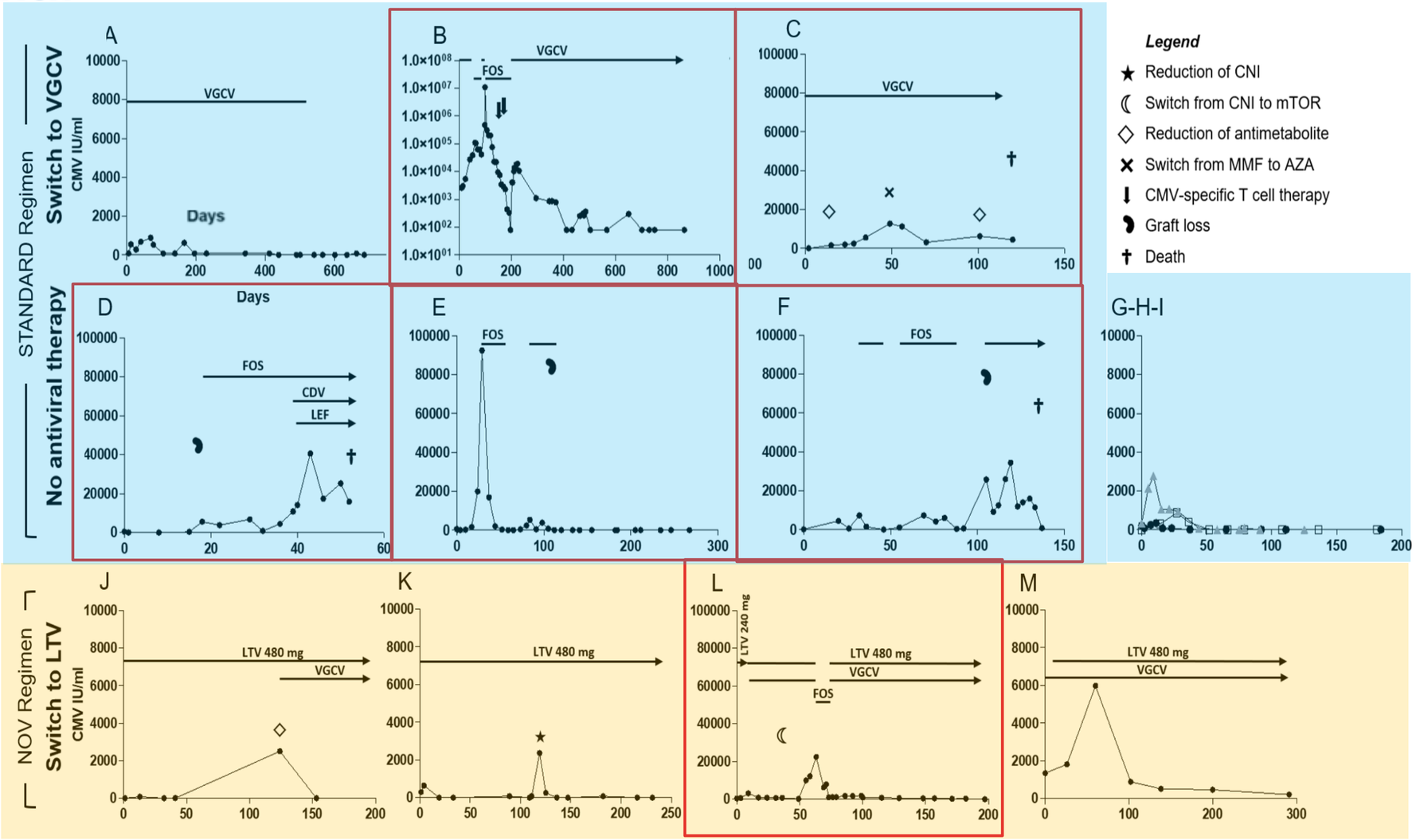

Conclusion: A switch from FOS to oral VGCV+LTV may be safe and efficacious in controlling CMV infection with less nephrotoxicity and improved patient outcome.

Nephro Update Europe 2020
18 – 19 September, Amsterdam (Noordwijk)

KIDNEY DISEASE

Disseminated Nocardiosis after ANCA-vasculitis

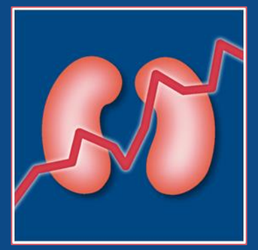

Maria do Mar Menezes, Portugal

Disseminated Nocardiosis after ANCA-vasculitis

Authors: Menezes, Maria do Mar; Cardoso, Filipa; Aires, Inês; Póvoas, Diana; Carvalho, Dulce; Calado, Joaquim; Ribeiro, Francisco; Nolasco, Fernando.

Nephrology Department, Hospital Curry Cabral, Centro Hospitalar Universitário Lisboa Central, Lisboa, Portugal.

Disseminated nocardiosis

69-year-old patient .

Medical history: chronic idiopathic thrombocytopenic purpura and T2D.

July 2019 ➡ **ANCA-PR3 VASCULITIS**

- Acute kidney injury sCr 6mg/dL; kidney biopsy - crescent glomerulonephritis and ANCA-PR3 9,092.8 UQ -> Hemodialysis
- Interstitial pulmonary involvement + tube dysfunction and deafness.

Treatment: Plasmapheresis, pulses of methylprednisolone and cyclophosphamide -> oral prednisolone + trimethoprim/sulfamethoxazole.

Outcome : sCr4.2mg/dL

October 2019

- High fever, chills, asthenia and myalgia. Physical exam unremarkable.
- Analytically: CRP 362 mg/L, Haemoglobin 9.4g/dL, sCr 5.4mg/dL.
- Chest X-ray: lobar pneumonia.
- Blood cultures: *Nocardia farcinica*
- Chest CT: “multiple nodular irregular areas with consolidation area with air bronchogram in the left upper lobe”.
- Cardiac and neurological involvement excluded.

Treatment: 6 weeks iv TMP-SMX + amikacin -> oral amoxicillin+clavulanic acid + TMP-SMX). Immunosuppression - prednisolone (5mg/day).

Outcome:

- Favorable evolution of lung lesions.
- sCr 5mg/dL.
- ANCA PR3 63UQ/L.

Conclusion: Nocardiosis is a rare opportunistic and serious bacterial infection, with the lung being the main affected organ, followed by central nervous system and skin.It is mainly associated with immunosuppression states, with few case reports in patients with systemic vasculitis.In these cases, a 63% cure rate is described.

The prophylaxis with TMP-SMX decreases,but does not completely prevent the onset of this disease, as it was verified.

Nephro Update Europe 2020

18 – 19 September, Amsterdam (Noordwijk)

KIDNEY DISEASE

Henoch-Schönlein purpura after Multiple Myeloma

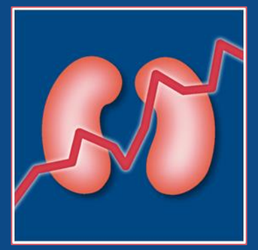

Maria do Mar Menezes, Portugal

Henoch-Schönlein purpura after Multiple Myeloma

Authors: Menezes, Maria do Mar[1]; Chuva Teresa[2]; Ferreira, Hugo[2]; Paiva, Ana[2]; Maximino Costa, José[2].

Affiliation:

1 – Nephrology Department. Hospital Curry Cabral, Centro Hospitalar Universitário Lisboa Central, Lisboa, Portugal.

2- Nephrology Department. Instituto Português de Oncologia do Porto Francisco Gentil Porto. Portugal.

Clinical case

71-year old woman

2002 - Hip plasmocytoma -> RT .

2007 - **Multiple Myeloma (MM) IgG kappa-**> Idarubicin + dexamethasone (Dex)

-> autologous hematopoietic stem cell transplantation -> complete remission.

2013 - Disease progression -> Bortezomib + thalidomide + Dex -> CR.

2017 – Relapse -> Thalidomide + cyclophosphamide + Dex + RT.

2018 – Acute kidney injury (eGFR 29 ml/min/1,73m2) +

Uric acid not doseable, P 1,7mg/dL, K+ 3.4meq/L, glycosuria,

+ fractional phosphate excretion 37%, non-selective proteinuria 900mg/24h

+ metabolic acidosis.

Fanconi syndrome

* Secondary to bisphosphonates ?

* Light chain proximal tubulopathy?

2019 - Bone pain + arthralgias + renal dysfunction sCr 8mg/dL + hematoproteinuria + diarrhea + lower limbs purpura -> Hemodialysis + empirical corticosteroids.

Immunologic study: Negative

No MM relapse.

Renal biopsy: Mesangio-proliferative glomerulonephritis with IgA deposits, scarce fibrous crescents,

focus of acute pyelonephritis, acute interstitial nephritis; marked tubulo-interstitial atrophy with 50% interstitial fibrosis

***Henoch-Schönlein* purpura**

She remained on steroids for 5 months and had a favorable recovery, with independence of HD.

At the time of the last appointment the patient had sCr 3,5mg/dL and no signs of disease progression.

Nephro Update Europe 2020

18 – 19 September, Amsterdam (Noordwijk)

DIALYSIS

An 18 Month Prospective Study: Vitamin D Supplementation in Hemodialysis (HD) – Is It Efficient and Is the Dose Sufficient?

Cátia Figueiredo, Portugal

An 18 Month Prospective Study: Vitamin D Supplementation in Hemodialysis (HD) – Is It Efficient and Is the Dose Sufficient?

Cátia Figueiredo, Rita Valério Alves, Hernâni Gonçalves, Karina Lopes, Flora Sofia, Ana Vila Lobos

Nephrology Department, Centro Hospitalar do Médio Tejo. Torres Novas, Santarém, Portugal.

Introduction & Methods

- Introduction: Hypovitaminosis D (vitamin D deficiency <20 ng/mL and insufficiency 20-29 ng/mL) is highly prevalent in HD patients. Although the efficacy of supplementation is uncertain, recent guidelines still recommend vitamin D supplementation in this population.
- Objective: The objective is to evaluate the efficacy of oral cholecalciferol supplementation and verify if maintenance dose used is enough to maintain a vitamin D levels >30ng/mL, in a hospital HD unit.
- Methods: Prospective study with 18 months follow-up period. HD patients were supplemented, 3 times a week, with 12000 IU cholecalciferol, if vitamin D level <30 ng/mL, and 4000 IU if above. Every 6 months (3 time points) vitamin D blood levels were measured. Statistical analysis was performed using SPSS version 21 for Windows.

Results & Conclusion

- Results: Sixty patients completed the follow-up period. The mean age was 74.70±1.43 years and 65% (n=39) were male. The mean vitamin D blood level at time point 0 was 11.73±0.77ng/mL and at time point 3 was 20.00±0.84ng/mL. Cholecalciferol supplementation significantly changed vitamin D blood levels along time (repeated measures ANOVA: $F(2.492;144.54)=26.832;p<0.001$), with a statistically significant increase from time point 0 to point 3 (+8.27ng/mL, $p<0.001$). Only at time point 2 there were vitamin D levels >30ng/mL (mean value 33.34±2.69ng/mL) in 7 patients (11.7%). However, until the end of follow-up period, there were a statistically significant decrease of vitamin D levels (-11.63±5.80ng/mL, $p=0.002$) and only 3 patients (5%) reached levels >30ng/mL. None of them were the patients who had values >30 ng/mL after 12 months.

- Conclusion: Although cholecalciferol supplementation had significantly increased vitamin D levels, only 7 patients reached values >30ng/mL, but none maintained those levels until the end of follow-up period. We concluded that the maintenance dose is probably insufficient, however more studies are needed to clarify about the most effective maintenance dose.

Nephro Update Europe 2020

18 – 19 September, Amsterdam (Noordwijk)

DIALYSIS

An 18 Month Prospective Study: Vitamin D Supplementation in Hemodialysis (HD) – Is It Efficient and Is the Dose Sufficient?

Cátia Figueiredo, Portugal

Predictors of 6 Month Mortality in Incident Hemodialysis Patients

Cátia Figueiredo, Rachele Escoli, Hernâni Gonçalves, Karina Lopes, Flora Sofia, Ana Vila Lobos

Nephrology Department, Centro Hospitalar do Médio Tejo. Torres Novas, Santarém, Portugal

Introduction & Methods

- Introduction: It is important to know early mortality factors in incident hemodialysis (HD) patients, especially at a time when the onset of dialysis in elderly patients with multiple comorbidities is becoming less liberal.
- Objective: The objective of our study is to evaluate the 6 month mortality predictive factors in incident HD patients.
- Methods: Retrospective observational study of incident HD patients between 01 January 2017 and 30 June 2019, in a hospital HD unit. At the time of hemodialysis induction were analyzed several clinical and analytical data. Logistic regression analysis was used to evaluate 6 month mortality predictors.

Results & Conclusion

- Results: The mean age of 163 incident HD patients was 70.63±3.9 years and 57.1% were male. We observed 26 (16%) deaths, 12 of which (46.15%) occurred in the first 6 months of hemodialysis. Pneumonia and cachexia were the major causes of mortality. Most patients who died within the first 6 months had hemoglobin values <10g/dL (83.3%) and albumin <2.5g/dL (58.3%), with a statistic significance (p=0.047 and p=0.011, respectively). There was a significant percentage of institutionalized patients who died within the first 6 months (41.7%;p=0.015) and institutionalization was an important mortality predictor [p=0.005;adjusted odds ratio (OR)10.4(CI:2.017–49.9)]. Patients with longer hospitalizations at the time of HD induction [(p=0.044;(OR):1.103;CI:1.003-1.213)] and albumin values <2.5mg/dL [(p=0.03;(OR):3.8(CI: 1.14-13)] also presented a higher risk of death at 6 months.

- Conclusion: These mortality predictive factors may reflect the aging of our chronic kidney disease patients, who have multiple comorbidities, requiring institutionalization and longer hospitalizations and, consequently, increased risk of mortality.

Nephro Update Europe 2020
18 – 19 September, Amsterdam (Noordwijk)

DIALYSIS

Mortality predictors on incident hemodialysis patients

Patrícia Valério, Portugal

Mortality predictors on incident hemodialysis patients

Patrícia Valério, Elsa Soares, Teresa Furtado, Patrícia Domingues, Ana Farinha

Presenting author: Elsa Soares

Setúbal Hospital Center, Portugal

Presentation

- **Introduction**
  - Several studies showed that patients with a higher comorbidities burden, have a lower early survival after starting hemodialysis (HD).
  - We assessed early mortality predictive factors in a cohort of incident HD patients.

- **Methods**
  - We retrospectively evaluate a cohort of HD patients, who started HD between 2014 and 2018. All patients were regularly followed in nephrology attendance for more than 3 months, and presented a vascular access in use.
  - We assessed survival status 3 months after starting HD.

- **Results**

208 patients

Male sex	142 (68,3%)
Median age, y-o	73 (26 to 92)
Elderly	160 (76,9%)

	Deceased patient N=73	Non-deceased N=135	*p*
Elderly (>65 y-o)	66 (90,4%)	94 (69,6%)	0.001
Diabetes	41 (56,2%)	59 (43,7%)	0.0001
Dementia	10 (13,7%)	4 (3,0%)	0.015
CVC induction	38 (52,1%)	25 (18,5%)	<0.0001
aCCI	7,6 ± 1,9	6,2 ± 1,9	<0.0001
eGFR induction	8,7 ± 3,7	7,1 ± 2,2	<0.0001

	Survival analysis *adjusted HR*
Dementia	3.59 (1.35-9.60)
CVC	3.30 (1.94-5.61)
Higher aCCI	1.40 (1.21-1.62)
Higher eGFR	1.14 (1.06-1.24)

CVC, central venous catheter; aCCI, age-adjusted comorbidity index; eGFR, estimated glomerular filtration rate.

Conclusion

- This results reflect an aged incident HD population, with multiple comorbidities, increasingly fragile.
  - The presence **of Dementia**, a **higher Charlson index** and **CVC on induction** reflect comorbidities burden.
  - The impact of higher **eGFR** in mortality could be explained by a group of patients with a higher onus of (uremic) symptoms, that nephrologists had difficulty to manage without to start kidney replacement therapy.
  - Age had no impact on early survival.

Nephrologists should put in perspective their attitude towards advanced chronic kidney disease, keeping in mind that Conservative Care may be the right choice for some patients.

Nephro Update Europe 2020
18 – 19 September, Amsterdam (Noordwijk)

DIALYSIS

Is there any benefit for anticoagulation in hemodialysis patients?



Carolina Ormonde, Portugal

Is there any benefit for anticoagulation in hemodialysis patients?

Ormonde, C.[1], *Ventura*, S.[1], *Cabral*, R.[1], *Brum*, S.[1], *Baptista*, M.[1], *Esteves*, J.[1]

[1] Nephrology Department, Hospital do Divino Espírito Santo, Azores, Portugal

There are no conflict of interests associated with the authors or the study.

Rationale

- Hemodialysis (HD) patients are at high risk of ischemic events (IE).
- Warfarin use is common but debatable in HD.
- Anticoagulant use in HD is not clear as in general population and practices vary among renal units.
- International guidelines differ in there recommendations for HD patients.
- **The aim of this study was to evaluate the benefits and risks of anticoagulation in HD patients**.

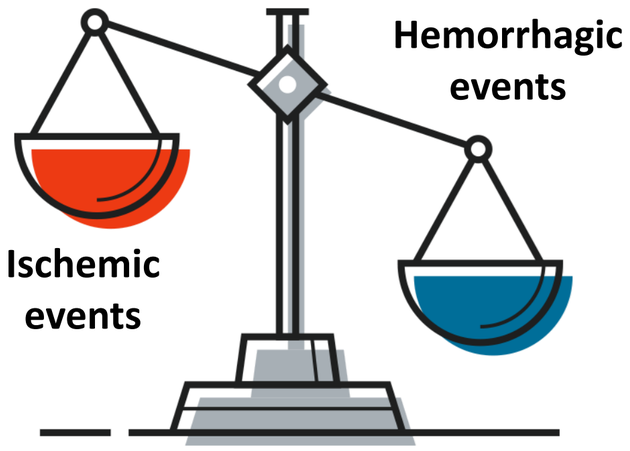

Methods

- Retrospective observational study in HD unit from Hospital do Divino Espírito Santo, Azores, Portugal
- Inclusion criteria: prevalent HD patients from January 2012 to April 2020
- Exclusion criteria: incident HD patients

- Demographic, clinical and analytical data was collected from the patient's charts
- Bivariate, multivariate and survival analysis using SPSS 25.0

- Patients were divided according to anticoagulation status – patients not anticoagulated were used as control group

Results

Baseline characteristics	All n=160	Warfarin group n=34	No anticoagulation group n=126	p value
Age – mean±std, years	62.1±14.8	66.09±12.7	61.6±15.2	0.078
Gender (male) – n (%)	96 (60.0%)	21 (61.8%)	75 (59.5%)	0.813
HD vintage – median (IQR), months	30 (12-52)	48 (23.5-99.5)	27 (11-47)	0.007
Atrial fibrillation – n (%)	33 (20.6%)	28 (82.4%)	5 (4.0%)	<0.0001
Antiplatelet therapy – n (%)	52 (32.5%)	12 (35.3%)	40 (31.7%)	0.695

No patients under new oral anticoagulants!

Outcomes comparison	Warfarin group n=34	No anticoagulation group n=126	p value
Ischemic events – n (%)	5 (14.7%)	12 (9.5%)	0.362
Hemorrhagic events – n (%)	19 (55.9%)	23 (18.3%)	**<0.0001**
All-cause mortality – n (%)	13 (38.2%)	45 (35.7%)	0.786
Death by hemorrhagic event – n (%)	3 (8.8%)	7 (5.6%)	0.531

Multivariate analysis

Adjusted to:
- ✓ Age
- ✓ HD vintage
- ✓ Antiplatelet therapy

OR 5.6
95% CI 2.3-13.5
p=<0.0001

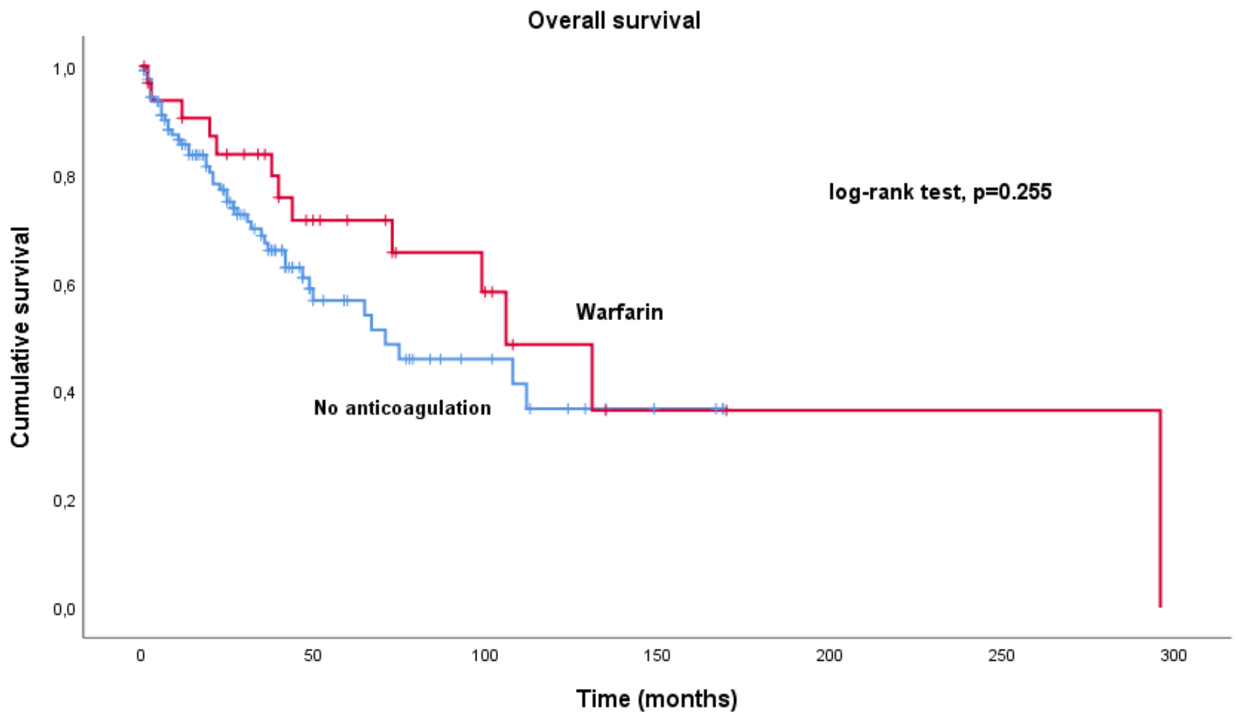

Conclusions

- ✓ Warfarin use was **common** in HD patients, mainly for AF.
- ✓ Warfarin **didn't** seem to **reduce IE** and was associated with **higher incidence of HE**.
- ✓ Nonetheless, there was **no association with decrease in survival**.

Nephro Update Europe 2020
18 – 19 September, Amsterdam (Noordwijk)

KIDNEY DISEASE

Clinico-pathological characteristics of patients with biopsy-proven acute interstitial nephritis in a portuguese center

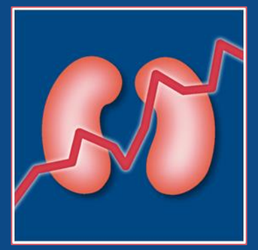

Luisa Costa, Portugal

CLINICO-PATHOLOGICAL CHARACTERISTICS OF PATIENTS WITH BIOPSY-PROVEN ACUTE INTERSTITIAL NEPHRITIS IN A PORTUGUESE CENTER

Costa L.[1] , Góis M. [2], Viana H. [2] , Nolasco F. [2]
[1] Nephrology Department, Centro Hospitalar Tondela-Viseu, Viseu, Portugal
[2] Nephrology Department, Hospital de Curry Cabral, Lisboa, Portugal

INTRODUCTION:

Acute interstitial nephritis (AIN) has a large spectrum of etiologies and is increasing world wide. As it is a well-recognized cause of acute kidney injury (AKI) but still underdiagnosed, detailed characterization of biopsy proven AIN of one center was made.

METHODS:

- Single-center retrospective observational cohort study.
- The study was undertaken at the Centro Hospitalar Tondela-Viseu, Viseu, Portugal.
- The period between January 2015 and July 2020 was selected in the renal biopsies database.
- The keywords “Nephritis” and “Interstitial” were used within the diagnosis.
- The keyword “chronic” was used do exclude chronic interstitial nephritis.
- Biopsy results were manually reviewed and those with coexistent histologic diagnosis at the time of biopsy of acute glomerulonephritis were excluded.
- Histological reports were reviewed.
- Medical records were consulted for the patient demographic information.
- Medical records were consulted for the renal markers, treatment and renal outcomes, including serum creatinine and need for renal replacement therapy.
- The chi-square independence test was used to evaluate if two categorical variables were related.

RESULTS:

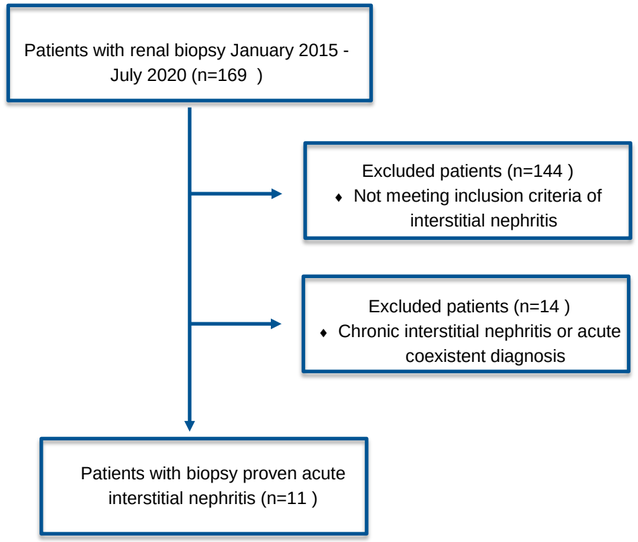

Graphic 1 - Flow diagram of patient selection process

	MEN	WOMEN	Total (N=11)
Gender	3	8	11
Mean age (years)	77,3	50,63	57,9
Comorbidities			
Heart failure	0	0	4
HBP	1	2	3
DM	2	3	5
Immune mediated disease	0	5	5
Dyslipidemia	2	2	4

Table 1 - Patients characteristics. HBP: High blood pressure; DM: Diabetes mellitus

	MEN	WOMEN	Total (N=11)
UWBC (HPF)			
0-10	3	4	7
10-100	0	4	4
>100	0	0	0
Proteinúria (g/day)			
< 0,15	0	0	0
0,150-3,5	3	8	11
>3,5	0	0	0
Serum eosinophils			
High	0		
Normal	3	8	11
AKIN Severity			
1	0	1	1
2	0	2	2
3	1	5	6

Table 2 - Renal Indices at time of biopsy. UWBC: urinary white blood cells, HPF: high power field

	MEN	WOMEN	Total (N=11)
Glomeruli			
Sclerotic glomeruli (nº of patients)	2	4	6
Interstitial infiltrate			
0-25%	0	0	0
25-50%	0	2	2
>50%	3	6	9
Tubules			
Tubulitis	1	4	5
Acute tubular necrosis	1	6	7
Tubular atrophy	1	2	3
Chronic vessels alterations	3	3	6

Table 3 - Histologic Findings

	MEN	WOMEN	Total (N=11)
Unknown	2	4	6
Drugs			
Antibiotics	0	0	0
NSAIDS	0	1	1
Other	1	2	3
Immune mediated disease	0	1	1

Table 4 - AIN Etiology. NSAIDs: Non-steroidal anti-inflammatory drugs; PPIs: Proton-pump inhibitors

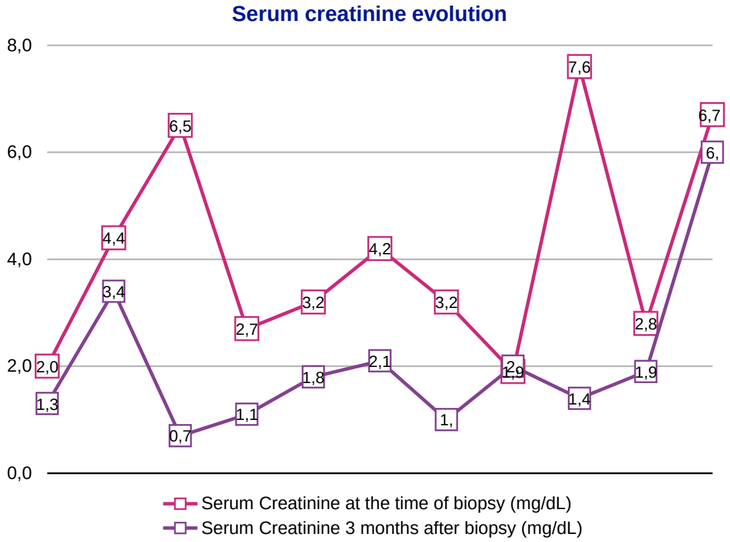

Graphic 2 - Serum Creatinine at the time of biopsy-proven AIN and 3 months after the diagno

▷ Of the ten patients treated with steroids, 8 had renal function improvement.

▷No patient required renal replacement therapy.

▷We did not find relation between high grades of either interstitial infiltrate or tubulitis and severity of AKI. (p=0,658 and p=0,201, respectively)

CONCLUSIONS:

▷ AIN has an important incidence, representing 14% of all the diagnoses made in biopsied women in the studied period.

▷ Our study emphasizes the importance of AIN diagnosis, since the majority of patients undergoing steroid treatment showed improvement of renal function.

Nephro Update Europe 2020

18 – 19 September, Amsterdam (Noordwijk)

DIALYSIS

OUTCOMES OF CUFF-SHAVING PROCEDURE IN EXIT-SITE INFECTION: EXPERIENCE IN 2 CENTRES

Rita Vicente, Portugal

OUTCOMES OF CUFF-SHAVING PROCEDURE IN EXIT-SITE INFECTION: EXPERIENCE IN 2 CENTRES

R Vicente (1); R Silva (1); F Silva (2); J Santos (1); N Pestana (3); I Santos (1); MJ Carvalho (2); M Amoedo (1); A Rodrigues (2); C Pires (1); A Cabrita (2)

(1) – Nephrology Department, Hospital do Espírito Santo, Évora, Portugal

(2) - Nephrology Department, Centro Hospitalar Universitário do Porto, Porto, Portugal

(3) - Nephrology Department, Hospital Central do Funchal, Funchal, Portugal

INTRODUCTION

Exit-site infection (ESI) of the peritoneal dialysis (PD) catheter remains a significant cause of catheter loss.

Shaving of the external cuff has been performed as a last resource for catheter salvage in complicated ESI, but with conflicting results.

METHODS

Retrospective study of PD patients in two different hospitals, who underwent external cuff-shaving to catheter salvage in complicated ESI.

SUCCESS was defined as a 3 MONTHS PERIOD FREE OF INFECTION (ESI or peritonitis) by the previous identified agent.

RESULTS

39 patients

CHARACTERISTICS

Male	49%
Age (mean ± sd)	47 ± 14 y
Diabetes	26%
Time on PD until shaving (median, IQR)	26 [10-43] m
Follow-up (median, IQR)	16 [7-28] m

Cuff-shaving procedure

51% → Chronic ESI

49% → Exuberant acute ESI

Most frequent agent → Staphylococcus aureus (n=18, 46%)

Gram negative bacteria – n=12, 31%

10 patients (26%) had ESI or peritonitis related with previous ESI in the first 3 months → catheter removal

Success rate **74%**

Cured group: 29 patients

31% had at least one peritonitis episode

34% developed another ESI

52% catheters were removed after an infection

0,36 episodes/patient-year
little higher than the global centres rate (0,30 and 0,34)

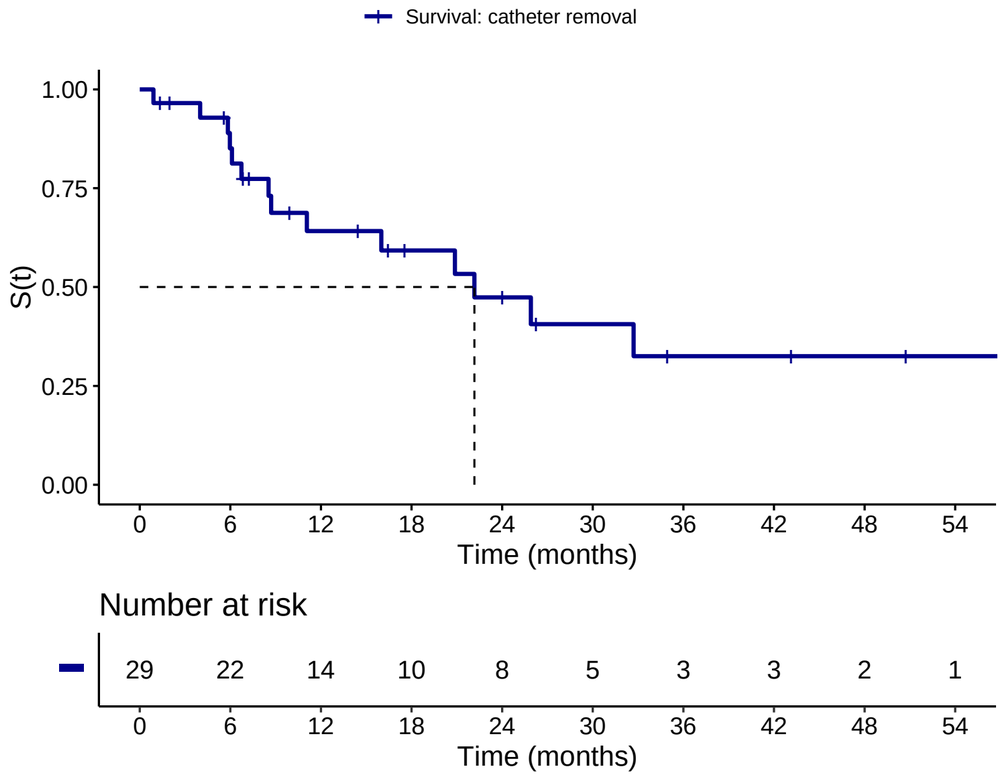

CONCLUSION

In our experience, cuff-shaving procedure in complicated ESI could immediately SALVAGE THE CATHETER in about THREE QUARTERS OF PATIENTS.

Our results encourage this procedure, which could prevent catheter removal and haemodialysis transfer.

Nephro Update Europe 2020
18 – 19 September, Amsterdam (Noordwijk)

OTHER

Kidney Transplantation in Recipients Older than 60 years – a center experience for the last 10 years

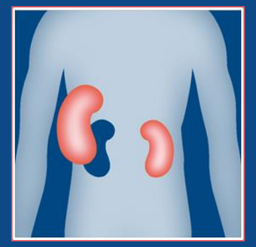

Filipa Silva, Portugal

Kidney Transplantation in Recipients Older than 60 years – a center experience for the last 10 years

Filipa Silva[1], Diana Fernandes[2], Joana Tavares[1], Ana Castro[1], Sofia Pedroso[1], Manuela Almeida[1], Jorge Malheiro[1], Cristina Freitas[1], João Pedro Pimentel[1], La Salete Martins[1], António Castro Henriques[1]

[1] Transplant and Nephrology Department, Centro Hospitalar e Universitário do Porto, Porto, Portugal

[2] Medicine Department, Unidade de Local de Saúde do Nordeste

Background and Aims:

- The number of patients older than 60 years with end-stage renal disease (ESRD) has increased and therefore, the number of elderly patients receiving a kidney transplant (KT) is also growing worldwide. However, earl post-transplantation mortality is still high in this specific population and outcomes have not, however, been fully defined.
- The aim of our study is to evaluate outcomes in older recipients in our transplantation center.

Methods:

- We performed a unicenter retrospective study with all the kidneys recipients older than 60Y from January/09 through December/18 (n=205). The follow-up period was at least 1 year.

Results:

- Their mean age was 64Y (±2,95, range: 60-73Y) and most of them were men (n=134). A total of 198 patients were on dialysis for 4,7± 2,4Y (min: 0,3, max 30,1Y). In 7 patients the transplant was preemptive. The main causes of ESRD were unknown (n=65), glomerular n=44) and diabetes (n=41). Most of the donors were deceased (n=181), mainly from cardiovascular (65%) and trauma causes (27%). Their mean age was 60± 7,9Y (range 21-78Y) and almost 40% of them were expanded criteria donors (n=72). From these 68 (94%) underwent pre-transplant renal biopsy.

Results (continuation):

- A considerable number of surgical complications occurred: 67 vascular and 32 urologic, in 27 patients needing surgical reinterventions 16±45,5 days after KT. The hospitalization duration was 13±8,6 days and more than 50% (n=115) of the recipients presented delayed graft function, 78 (38%) requiring dialysis. In 88% (n=101) of them cause was acute tubular necrosis.
- The most common complications were infectious disease (n=99) following by cardiovascular events (n=50) and malignancies (n=42). Skin malignancies were the most frequent, occurring in 55% (n=23) of recipients. At the end of follow-up, death occurred in 29 patients (14%) 7 of them during the hospitalization period after KT. The main causes were infection (n=13) and cardiovascular disease (n=7). The first cause of graft loss was death with functioning graft (n=26), following rejection(n=6) and vascular and urologic complications (n=3 each one).
- At December/19 the mean estimated glomerular filtration rate was 51,3±20ml/min per 1,73m^2.

Conclusion:

- In general, selected elderly ESRD patients can benefit from a KT, in terms of life expectancy and improved quality of live, compared to dialysis. However, it is important to recognize that they may have a more complicated posttransplant course. It is essential a case-by-case individualization, rather than generalizations about therapeutic options based on age alone.

Nephro Update Europe 2020
18 – 19 September, Amsterdam (Noordwijk)

KIDNEY DISEASE

Acute kidney injury in patients with severe COVID-19: a single center experience

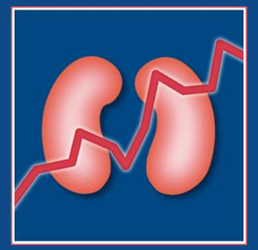

Jennifer Scotti Gerber, Switzerland

Acute kidney injury in patients with severe COVID-19: a single center experience

Nicola Beria, Jennifer Scotti Gerber, Giorgia Bianchi, Pietro Cippà
Division of Nephrology, Ente Ospedaliero Cantonale
Lugano and Locarno, Switzerland

Objective of the study

Knowing that acute kidney injury is an important manifestation of COVID-19, we report our experience in patients admitted to the intensive care unit (ICU) of a dedicated COVID-19 hospital during the first COVID-19 wave in Ticino, Switzerland.

Methods

Retrospective analysis of patients admitted to the intensive care unit (ICU) of Regional Hospital of Locarno, Switzerland Between March 1st and May 31st 2020

Results

Figure 1.
Incidence of AKI in COVID-19 patients admitted to the ICU

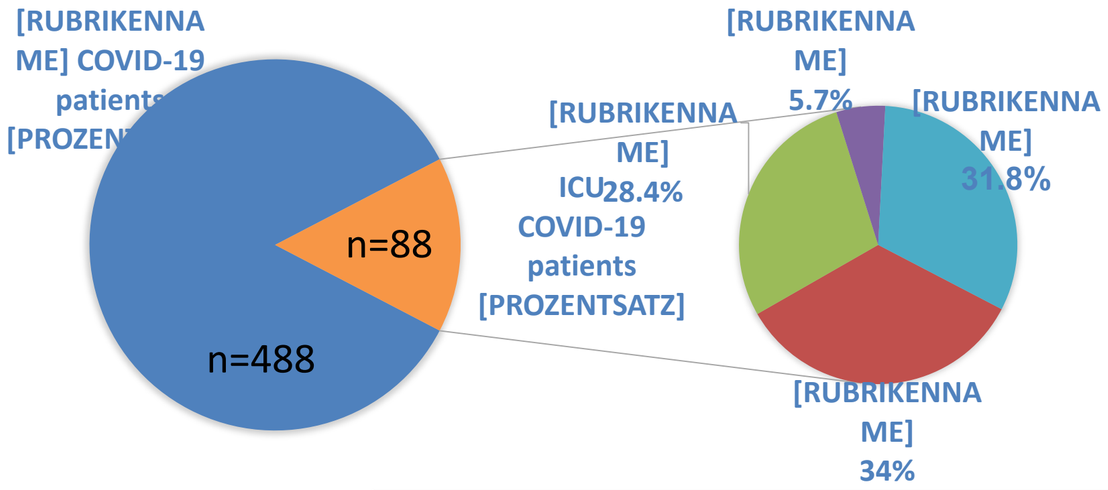

Table 1.
Baseline characteristics

	AKI (n = 58)	Non-AKI (n = 30)	P-value
Male	42	20	0.62
Age (median)	69.5	67	0.052
Hypertension	33	15	0.65
Diabetes mellitus	19	6	0.32
Chronic kidney disease			
stage 3	13	3	0.24
stage 4-5	5	2	1
Smoker	7	6	0.35
Previous ACEi/ARBs therapy	23	10	0.64
BMI in kg/m2 (median)	30.2	30	0.51

Results

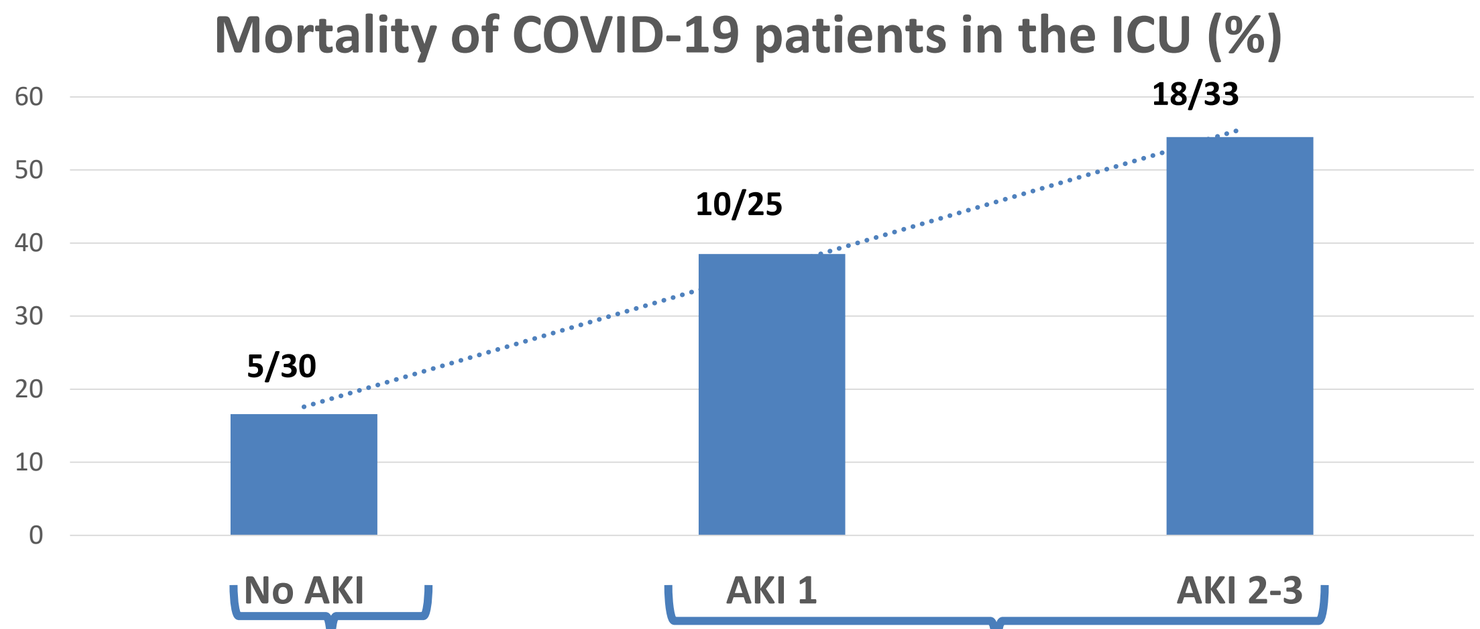

P=0.005

P-value for trend=0.02

Conclusion

AKI is a frequent manifestation of severe COVID-19 and is strongly associated with mortality.

Nephro Update Europe 2020
18 – 19 September, Amsterdam (Noordwijk)

OTHER

Polyomavirus nephropathy: data from 12 years with Banff 2017 classification

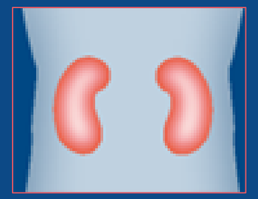

Filipa Cardoso, Portugal

CENTRO HOSPITALAR DE LISBOA CENTRAL, EPE

Polyomavirus nephropathy:

data from 12 years with Banff 2017 classification

Authors: Filipa Cardoso[1], Mário Góis[1], Helena Viana[1], Marco Mendes[1], Ana Carina Ferreira[1], Fernando Nolasco[1]
Nephrology department, Hospital Curry Cabral – Centro Hospitalar Universitário Lisboa Central, E.P.E, Lisbon, Portugal

Polyomavirus nephropathy

- **Rationale/Objective**: Polyomavirus nephropathy is a common viral infection of renal allografts, with biopsy-proven incidence of approximately 5%. A generally accepted morphologic classification of definitive PVN that groups histologic changes, reflects clinical presentation, and facilitates comparative outcome analyses was lacking, until Banff 2017 classification emerged, dividing this disease into three classes, in which the worse outcome is linked to the higher classes.
- **Methods**: Retrospective analysis of patients diagnosed with PVN in the last 12 years. The minimum duration of follow-up was 18 months and maximum of 36 months. Demographic, laboratory and histological characteristics were studied. The primary endpoint was graft failure at 12, 18, 24 and 26 months. Continuous variables were presented as means or medians, according to normality and categorical variables presented as frequencies. STATA 14.2 statistical package was used and $p < 0.05$ was considered statistically significant.

Polyomavirus nephropathy

- **Results**: We identified 15 patients with NVP, mainly **male** (87%), **Caucasian** (67%) and deceased donor renal transplantation (87%), with a mean age of 57 years. The majority underwent induction therapy with thymoglobulin (80%) and mycophenolate mofetil (MMF), tacrolimus and prednisolone were used in 100% of the patients as maintenance treatment. **Thirty-three percent (n=5) were class 1, 53% (n=8) class 2 and 13% (n=2) class 3**. Mean serum creatinine (Scr) at first viremia (FV) was 1.96mg/dL (1,5-2,3) and 2,6mg/dL (2-3,8) at graft biopsy. Mean tacrolimus level before viremia was 8,3ng/mL (6,3-10,3). Immunosuppression reduction occurred in 100% of patients, in which 40% (n=6) switched to a mTOR inhibitor, 47% (n=7) performed intravenous immunoglobulin, 33% (n=5) ciprofloxacin and 73% (n=11) leflunomide. Mean initial polyoma viral load (PVL) was 45965 (4378-360800) and 270470 (35200-1496000) at graft biopsy. During 36 months of follow-up, PVN cleared in only 8 patients (53.3%), while 5 (33.3%) were on hemodialysis, of which 80% (n=4) were class 2 and only 20% (n=1) was class 1, showing a worse outcome in higher classes.

- **PVL** (both initially and at graft biopsy) was associated with graft loss (p=0.009 and p=0.02). There was also a connection between **higher Banff classes and higher Scr** at 24 (p=0.049) and 36 months (p=0.01). While initial Scr had no correlation with graft loss, **Scr at graft biopsy** was associated with our outcome (p=0.0095): 2.4mg/dL for those with a functioning graft and 4.2mg/dL for those on dialysis. **Age** showed a trend towards statistical significance (p=0.06) with our outcome, with **younger patients showing higher percentages of PVN clearance** (p=0.04). **Sex, race and donor type did not show any correlation**. Neither immunosuppression reduction nor the use of specific drugs showed any association with graft loss, although **MMF suspension** correlated with **PVN clearance** (p=0.03).

- **Conclusions**: Although a small sample, we conclude that there is an association between higher Banff classes and the need for hemodialysis, with higher Scr. PVL also has prognostic value. An early histologic diagnosis is essential and will add value to clinical information. This classification is a crucial cornerstone to improve comparability of clinicopathologic studies, outcome results, and therapeutic trials in order to attain an effective treatment.

OTHER

CHRONIC INTERSTITIAL NEPHRITIS BY INDINAVIR CRYSTALS

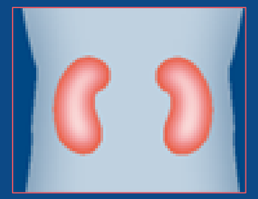

Joana Marques, Portugal

CHRONIC INTERSTITIAL NEPHRITIS BY INDINAVIR CRYSTALS

Marques, Joana[1]; Barata, Rui[1]; Carvalho, Dulce[1]; Góis, Mário[1]; Sousa, Helena; Nolasco, Fernando[1]

[1] Nephrology Department, Hospital Curry Cabral, Centro Hospitalar Universitário de Lisboa Central

Presentation

45-years old
w/ HIV-1 infection for 10 years with good immunovirulogical control under therapy with indinavir, lamivudine and zidovudine.
w/ untreated HCV genotype 4 infection.

[Referred for] Chronic renal disease » sCr =2.7 mg/dL

Anemia (Hb 10.6 g/dL)
Cryoglobulins (IgM 18.00 mg/dL)
Urine - erythrocyturia, proteinuria of 600mg/g
US - microlithiasis

✓Interstitial inflammatory infiltrate a
✓Atrophic tubules with intraluminal clefts
»» suggesting the presence of crystals.

CHRONIC INTERSTITIAL NEPHRITIS due to deposition of **INDINAVIR CRYSTALS**

TREATMENT Indinavir suspention

Stable back then ✓

Conclusion

- **RENAL INVOLVEMENT** in HIV infection is common but widely variable.
  - It may be related or not to systemic infection; associated with pharmacological toxicity, infections or others.
  - All kidney compartments can be affected.

- **Protease inhibitory drugs**, such as indinavir, are excreted in the urine and insoluble in their physiological pH, which may precipitate and form **crystals**.
  - Co-infection with HCV can favor this process.
  - Although crystalluria to indinavir is a common incidental finding, it is generally asymptomatic (67%) and/or associated with nephrolithiasis (4%).
  - **Indinavir nephropathy is rarely reported.**

- Since the differential diagnosis of kidney injury associated with HIV infection is complex, KB allows for a quick diagnosis and subsequent therapeutic guidance. If involved, interruption of the drug is mandatory.

Nephro Update Europe 2020

18 – 19 September, Amsterdam (Noordwijk)

DIALYSIS

Raoultella planticola urosepsis in a hemodialysis patient

Magda Sofia Ventura, Portugal

Raoultella planticola urosepsis in a hemodialysis patient

Authors: Ventura, M. S.; Ormonde, C.; Cabral, R.; Brum, S.; Baptista, M.; Esteves, J.

Affiliation: Nephrology Department, Hospital do Divino Espírito Santo, Ponta Delgada, Portugal

Disclosure: Nothing to disclose

Raoultella planticola

Very rare human pathogen with a high prevalence in soil and water

Rarely causes infection in healthy individuals – higher risk for diabetic patients and end-stage renal disease requiring dialysis

Few cases of urinary tract infection (UTI) have been reported in literature

Overall, infections from this agent have good prognosis

- ✓ 43-year-old female
- ✓ Dialysis-dependent, hypertension, diabetes mellitus, mild obesity
- ✓ Dysuria, polaquiuria and fever (38,9ºC) during hemodialysis (HD) session. No other symptoms
- ✓ Blood tests: 14310 leukocytes/uL, 12600 neutrophils/uL and elevated C-reactive protein (20.7mg/dL)
- ✓ Blood cultures were obtained, and urine culture was ordered
- ✓ **Vancomycin and levofloxacin** were initiated empirically
- ✓ Patient was discharged from hospital (maintaining surveillance in HD sessions)

Blood cultures flagged positive for a gram-negative agent → Vancomycin was interrupted

Raoultella planticola was identified

Antimicrobial susceptibility test:

- Sensitive to amoxicillin-clavulanate, cefuroxime, ciprofloxacin and trimethoprim-sulfamethoxazole

IV levofloxacin was continued, in HD sessions

- ✓ Patient showed a good response both clinically and in blood tests
- ✓ Control blood cultures (7th day of treatment) were negative
- ✓ Therapy was discontinued after 10 days

CONCLUSION

We presented the case of a HD-patient with comorbidities that are commonly present in *R. planticola* infections and a clinical presentation consistent with UTI

It is important to be aware of the existence of this rare pathogen, as targeted treatment is crucial.

Particularly, in our patient, the choice of levofloxacin allowed for outpatient treatment

Contaminated water is a possible source of infection, and it is fundamental to avoid its use in HD population, which in average contacts with >360L of water per week

Nephro Update Europe 2020
18 – 19 September, Amsterdam (Noordwijk)

DIALYSIS

Catheter-related *Elizabethkingia* miricola bacteraemia in a hemodialysis patient

Magda Sofia Ventura, Portugal

Catheter-related *Elizabethkingia miricola* bacteraemia in a hemodialysis patient

Authors: Ventura, M. S.; Ormonde, C.; Cabral, R.; Brum, S.; Baptista, M.; Esteves, J.

Affiliation: Nephrology Department, Hospital do Divino Espírito Santo, Ponta Delgada, Portugal

Disclosure: Nothing to disclose

HDES

Elizabethkingia are gram-negative bacteria that are emerging as human pathogens; associated with a high mortality rate
Early recognition is critical to ensure patients receive appropriate diagnosis and treatment

39-year-old woman in hemodialysis treatment (HD), via tunneled catheter on right jugular internal vein (due to vascular exhaustion)

Febrile episode during HD

- Without other complains
- Blood cultures were obtained and IV gentamicin was started

Gram-negative bacteria of difficult characterization

- Without further information
- Biological sample was sent to Portuguese National Institute of Health for characterization

Patient showed good response to treatment

- Total time of treatment: 14 days, IV
- No more febrile episodes, no symptoms or complaints

One month after this episode, patient presented with same clinical picture – we admitted reinfection

- ✓ Febrile episode, 40ºC, with difficult response to antipyretics. Without other clinical symptoms
- ✓ Blood cultures were again ordered, and patient was admitted in-hospital

Characterization previously ordered was positive for *Elizabethkingia miricola*

We started IV treatment with ciprofloxacin and trimethoprim/sulfamethoxazole

- ✓ Being the likely source of infection, we excised the tunneled cateter and reinsertion was performed after 48 hours
- ✓ Blood cultures were positive for the same specimen
- ✓ Patient completed in total 15 days of antibiotics (IV and orally), without further complications

CONCLUSION

Clinical suspicion and urgent start on antibiotics are important for the success of treatment in sepsis, especially in **multirresistant bacteria** like *Elizabethkingia*	Most clinical laboratories are unable to identify these species that, although emerging, were recently recognized as pathogens	Since we did not have antimicrobial susceptibility testing, we performed a combination of previously reported antibiotics, with good response

Nephro Update Europe 2020
18 – 19 September, Amsterdam (Noordwijk)

KIDNEY DISEASE

Acute kidney injury in the context of inflammatory bowel disease - a clinical case

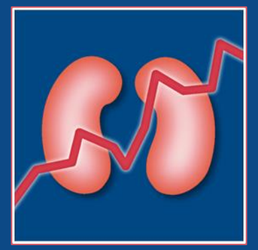

Joana Marques, Portugal

Acute kidney injury in the context of inflammatory bowel disease - a clinical case

Marques, Joana[1]; Barata, Rui[1]; Lemos, Joana[2]; Navarro, David; Marques, Bernardo; Mendes, Marco; Góis, Mário[1]; Sousa, Helena[1]; Ribeiro, Francisco; Nolasco, Fernando[1]

[1] Nephrology Department, Hospital Curry Cabral, Centro Hospitalar Universitário de Lisboa Central
[2] Gastroenterology Department, Instituto Português de Oncologia de Lisboa

Presentation

68-years old
w/ ulcerative colitis for 22 years. Steroid dependent . Difficult to control.

STABLE

Corticosteroids reduction
Messalazine increase.

sCr = 0.95 mg/dL.

1 month later

Progressive anorexia and peripheral edema
Anemia (Hb 10,7 g/dL) and **AKI** (sCr 2.4 mg/dL)

Serum circulating immunocomplexes (89.31 RU/mL)
Proteinuria of 237 mg/g; dysmorphic leukoerythrocyturia

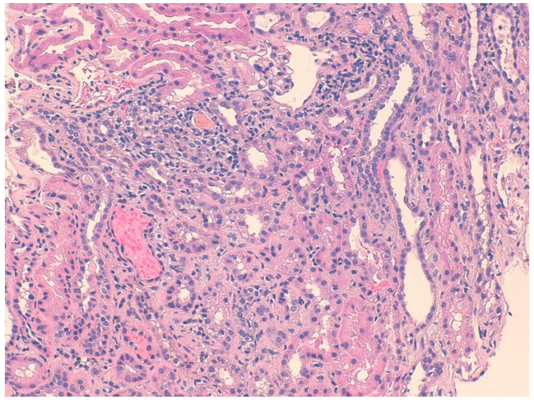
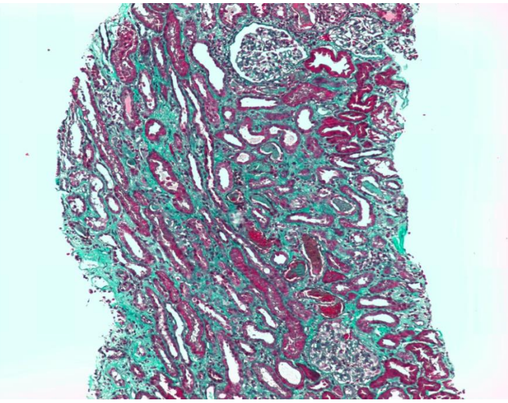
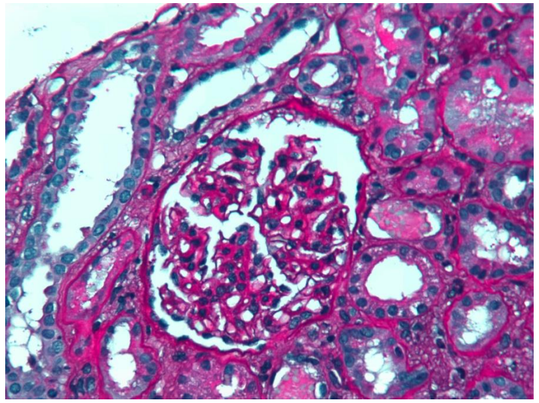
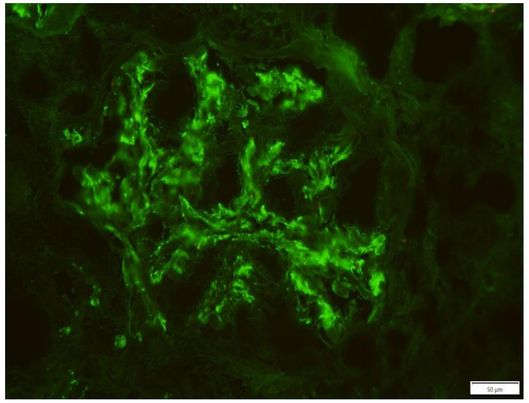

- Mononuclear interstitial inflammatory infiltrate
- Tubular hematuria
- Mesangial expansion with deposition of IgA and C3

✓Interstitial nephritis to salicylates
✓IgA nephropathy associated with IBD

TREATMENT

Messalazine suspension
Prednisolone 1mg/kg/dia - 2 month

Total recovery ✓

Conclusion

- Extraintestinal manifestations of inflammatory bowel disease are common and extendable to all organs are widely used in the management of IBD.
- **Renal involvement** occurs in 4-20% of cases. This may be dependent on IBD activity or not, secondary to metabolic disorders, drugs or others.
- **Interstitial nephritis** induced by **5-Aminosalicylate compounds** occurs <1/500 treated patients.
  - ✓ It is nonspecific and usually asymptomatic; AKI occurs late.
  - ✓ Relationship between dose and the risk of AKI is not linear, but it's considered an idiosyncratic hypersensitivity reaction.
  - ✓ Early interruption of the agent is central and treatment with corticosteroids is associated with better outcome.
  - ✓ 13% of patients may progress to end stage renal disease.

OTHER

Infectious transverse myelitis after kidney transplant – when the skin has the clue

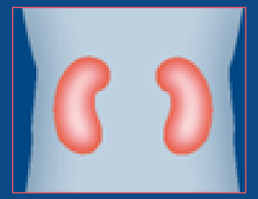

Inés Coelho, Portugal

Infectious transverse myelitis after kidney transplant – when the skin has the clue

Coelho I.[1], Alfaro L.[2], Silva F.[3], Fonseca D.[2], Salgado K.[2], Wagner D.[4], Viana L.[2], Vaz M.L.[2], Tedesco H.[2], Pestana J.M.[2]

1 – Nephrology Department, ULS Castelo Branco, Castelo Branco, Portugal.

2 - Nephrology Division, Hospital do Rim - UNIFESP, São Paulo, Brazil.

3 - Nephrology Department, Centro Hospitalar e Universitário do Porto, Porto, Portugal.

4 - Infectious Diseases Division, Hospital do Rim - UNIFESP, São Paulo, Brazil.

Case report

41-year-old mixed race female. History of end stage kidney disease due to ADPKD. **March 2015**: started hemodialysis. **September 2015**: first kidney transplant attempt that was lost 7 days after implantation due to thrombosis in. At that time, Protein S deficiency was diagnosed and she started chronic anticoagulation. **October 2019**: second kidney transplant from a deceased donor, complicated by an acute antibody mediated rejection at postoperative day 16 treated with plasmapheresis and immunoglobulin. Maintenance medication: mycophenolic acid, tacrolimus and prednisone.

January 2020 she was admitted with an acute urinary retention, numbness and weakness of the left lower leg affecting her walk.

- On **physical examination**, crostous lesions were detected on the left buttock that corresponded to a vesicular rash noticed two weeks previously, without other symptoms. Neurologic examination indicated that the strength of the proximal half (grade 3/5) and the distal half (grade 4/5) of the left lower leg decreased. The sense of pain and temperature below left knee also decreased. She had no history of herpes zoster infection or vaccination.

Investigation

- **Magnetic resonance:** diffuse hyperintensity signal at spinal cord levels T4, T7, T9 and T12 on T2-weighting (arrows).

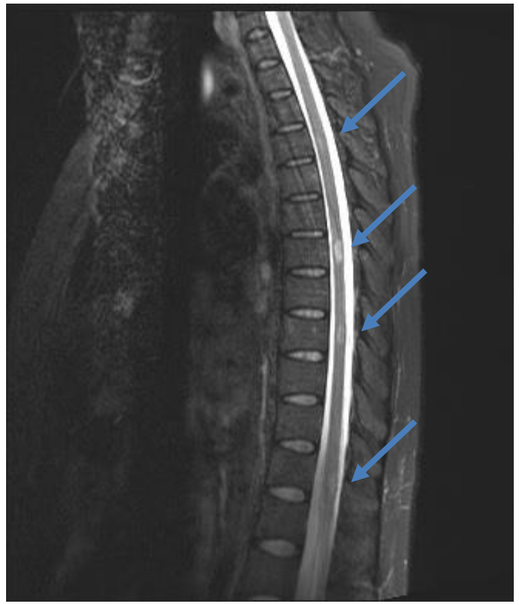

- **Cerebrospinal fluid (CSF):** elevated pressure and moderate lymphocytosis (50/microL). Varicella-zoster virus (VZV) DNA was detected by PCR amplification in CSF, confirming the diagnosis of **VZV transverse myelitis.**

Evolution

She was treated with intravenous acyclovir (750 mg 12/12h) during 21 days, with improvement of the gait abnormalities and neurogenic bladder although she still needs self-catheterization once daily with drainage <200mL.

Take-home messages

- Acute transverse myelitis (TM) is a neuro-inflamatory spinal cord disorder that presents with the rapid onset of weakness, sensory alterations, and/or bowel and bladder dysfunction.
- TM is rare (1-8 new cases per million) even in immunocompromised patients. It can be a challenging diagnosis and clinical suspicion is crucial.
- TM could be idiopathic or secondary to systemic inflammatory autoimmune condition, infectious or multifocal central nervous system disease.
- Infections from Varicella-zoster virus (VZV) can have devastating neurologic outcomes without prompt and appropriate treatment.
- Vaccination against VZV is recommended for solid organ transplant candidates who are ≥ 50 years old, and should ideally be given before transplantation to help ensure maximal immune response.

Bibliography: Baldwin KJ, Cummings CL. Herpesvirus Infections of the Nervous System. Continuum (Minneap Minn). 2018;24(5, Neuroinfectious Disease):1349-1369. doi:10.1212/CON.0000000000000661

Nephro Update Europe 2020
18 – 19 September, Amsterdam (Noordwijk)

KIDNEY DISEASE

Rivaroxaban related nephropathy

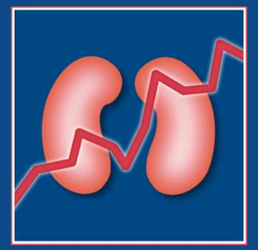

Luisa Costa, Portugal

RIVAROXABAN RELATED NEPHROPATHY

Costa L., Rodrigues A., Ferreira C., Lima C., Oliveira M., Lemos S.
Nephrology Department, Centro Hospitalar Tondela-Viseu, Portugal

INTRODUCTION:

Anticoagulant nephropathy, (ARN) initially described with warfarin, has recently been also identified with the new oral anticoagulants (NOACs). It is an entity with a complex pathophysiology that can result in some patients, in irreversible acute kidney injury (AKI) and has been recognized its association with increased renal morbidity and all-cause mortality.

Typical histological findings consist of extensive glomerular hemorrhage with tubular occlusion by red blood cells casts.

CASE REPORT 1

82 year old caucasian woman, admitted to the emergency department with 3 days of gross haematuria.

Past medical history:
Previous normal function (**serum creatinine 1.0 mg/dL**)
Arterial hypertension, type 2 diabetes, hyperlipidaemia, congestive heart failure and atrial fibrillation

Daily Medication:
Rivaroxaban 20 mg id for 2 months, furosemide, amlodipine, perindopril, atorvastatin, long-acting insulin

Physical examination: unremarkable.

Laboratory tests:
Creatinine 5.0 mg / dL, Urea 203 mg /dL
Urinalysis revealed **proteinuria** (**560 mg/day**) and **erythrocyturia** (**5900µL**)
Serum and urinary proteins electrophoresis showed no monoclonal component
Negative serology
Negative antinuclear antibodies and anti-neutrophil cytoplasmic antibodies
Normal complement

Renal ultrasound: normal-sized kidneys, with preserved corticomedullar differentiation

DIAGNOSIS: HYPERTENSIVE NEPHROANGIOSCLEROSIS AND ANTICOAGULANT- RELATED NEPHROPATHY.

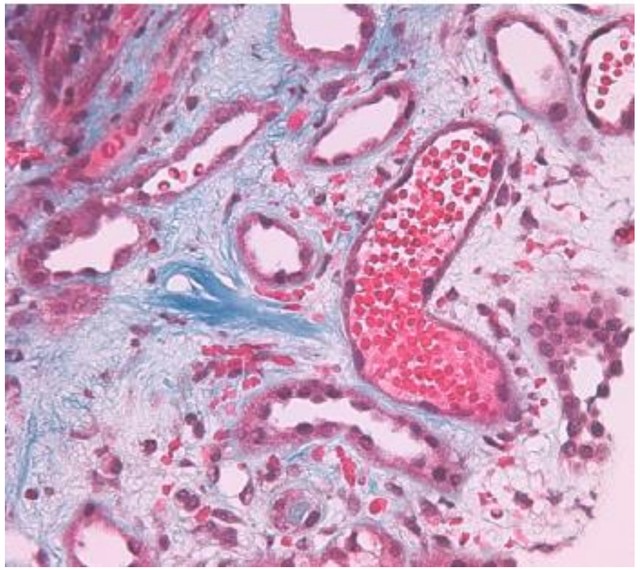

Image 1

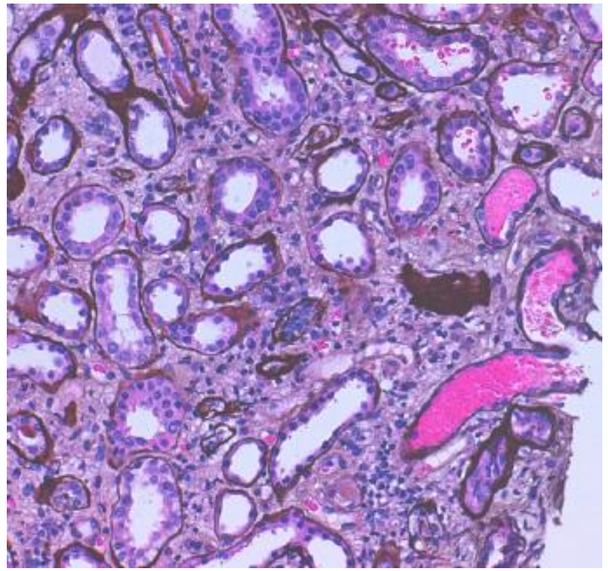

Image 2

Image 1: Masson trichrome staining x400: red blood cells casts and interstitial hemorrhage. Image 2: Methenamine silver staining x200: red blood cells casts

LIGHT MICROSCOPY	
Glomeruli	6 glomeruli. 3 glomeruli: total sclerosis due to ischemia.
Interstitium	Interstitial fibrosis throughout the fragment and chronic inflammatory infiltrate
Tubules	Most tubes are atrophic with very thick basals. **Presence of several hematic cylinders** and some tubular necrosis.
Vessels	An interlobular artery with thickening of the intima and internal elastic duplication. Some arterioles with lumen filling due to thickening of the intima

TREATMENT AND EVOLUTION: RIVAROXABAN WAS SUSPENDED AND ENOXAPARIN WAS STARTED AT A THERAPEUTIC DOSE, HOWEVER WITHOUT RENAL FUNCTION RECOVERY, HAVING STARTED HEMODIALYSIS 2 MONTHS AFTER DIAGNOSIS.

CASE REPORT 2

72 year old caucasian man, send to the emergency department after **AKI** detected in ocasional laboratory test

Past medical history:
Chronic kidney disease (**Creatinine 2.6mg / dL**), diagnosed one month ago, Arterial hypertension, dyslipidemia, heart failure, atrial fibrillation.

Daily Medication:
Rivaroxaban 20mg for 3 years ,enalapril, lercanidipine, bisoprolol, furosemide, allopurinol

Physical examination: High blood pressure, further physical examination was unremarkable

Laboratory tests:
Creatinine 4.4 mg / dL, Urea 100mg /dL
Urinalysis revealed **proteinuria** (**1,04 g/day**) and **erythrocyturia** (**10183/µL**)
Serum and urinary proteins electrophoresis showed no monoclonal component
Negative serology
Negative antinuclear antibodies and anti-neutrophil cytoplasmic antibodies
Normal complement

Renal ultrasound: normal-sized kidneys with reasonable corticomedullar differentiation.

DIAGNOSIS: SEGMENTAL FOCAL GLOMERULOSCLEROSIS AND ANTICOAGULANT- RELATED NEPHROPATHY.

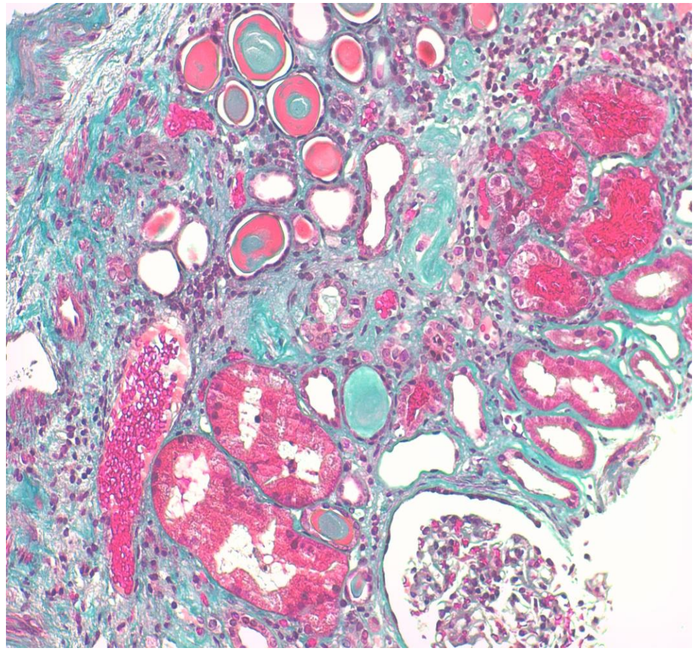

Image 3

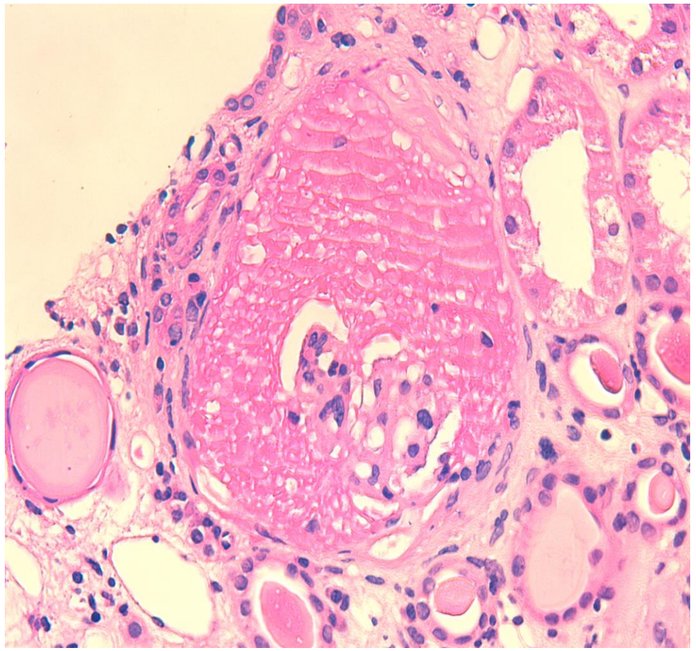

Image 4

Image 3 Masson trichrome staining x200: Medium and large caliber arteries with fibrotic intima hypertrophy, tubules filled with red blood cells casts; areas of interstitial hemorrhage; tubular atrophy; banded fibrosis. Image 4: Hematoxylin-Eosin staining, x400: presence of erythrocytes in the urinary space of the glomerulus

LIGHT MICROSCOPY	
Glomeruli	1 glomerulus: segmental sclerosis lesion. **Various glomeruli: presence of erythrocytes in the urinary space**.
Insterstitium	**Areas of interstitial hemorrhage.** Striped fibrosis occupying 70% of the cortex, with chronic inflammatory infiltrate.
Tubules	Tubular atrophy. **Several tubules filled with erythrocyte cylinders.**
Vessels	Medium and large caliber arteries with fibrotic hypertrophy of the severe intima

TREATMENT AND EVOLUTION: RIVAROXABAN WAS DISCONTINUED AND SWITCHED TO APIXABAN. THE PATIENT WAS DISCHARGED WITH IMPROVED RENAL FUNCTION (CREATININE 2.4MG / DL). 1 MONTH LATER, HE HAD SERUM CREATININE OF 1.9MG /DL.

CONCLUSIONS:

With the increasing use of NOACs, its importante the awareness of ARN, in order to identify this entity early through monitoring renal function.

The risk factors identified so far include, in addition to CKD, advanced age, hypertension, diabetic nephropathy and heart failure. The main preventive measure is the adjustment of anticoagulant dose, particularly in CKD patients, who are most susceptible to this iatrogeny.

Nephro Update Europe 2020
18 – 19 September, Amsterdam (Noordwijk)

OTHER

Simultaneous liver kidney transplantation – how can we improve?

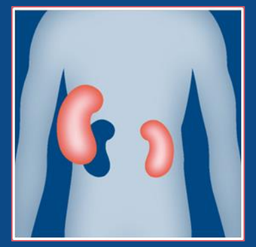

Filipa Cardoso, Portugal

CENTRO HOSPITALAR DE LISBOA CENTRAL, EPE

Simultaneous liver kidney transplantation – how can we improve?

Authors: Filipa Cardoso[1], Mário Góis[1], Helena Viana[1], Marco Mendes[1], Ana Carina Ferreira[1], Fernando Nolasco[1]
Nephrology department, Hospital Curry Cabral – Centro Hospitalar Universitário Lisboa Central, E.P.E, Lisbon, Portugal

Simultaneous liver kidney transplantation

- **Rationale/Objective**: Simultaneous liver kidney transplantation (SLKT) is a therapeutic option for some patients on a waiting list for liver or kidney transplantation, but due to organ shortage, there must be a clear benefit versus an isolated liver transplant.

- **Methods**: We performed a retrospective analysis of the 26 SKLT performed in our unit between 2004 and 2019. Median follow-up time was 38 (10-67) months. Our primary endpoint was graft failure and death by any cause. P < 0.05 was considered statistically significant.

Simultaneous liver kidney transplantation

- **Results**: We identified 26 patients, mainly male (57%) and Caucasian (92%). Sixty-nine percent were on dialysis before SKLT. Ten patients died (38.5%) after 20-month follow-up. Of those who survived, 6 lost their kidney graft (37.5%) at the end of follow-up, while only one lost his liver graft. There were 3 indication groups for SLKT: predominantly hepatic, renal or both. Those in the first group showed a trend towards statistical significance (p=0.06) for higher mortality, along with those with higher MELD values. There was a correlation between predominantly renal indication and less kidney failure (p=0.04). Dialysis after SKLT was linked with higher graft loss (p=0.04) and showed a trend towards statistical significance for increased mortality (p=0.05). Both Caucasian and older age (52.5+-8.5) were associated with more rejection episodes (p=0.02 and p=0.03). Bilirrubin, sex and comorbidities did not show any correlation.

- **Conclusions**: There is an association between higher Banff classes and the need for hemodialysis. PVL also has prognostic value. An early histologic diagnosis is essential and adds value to clinical information.

Nephro Update Europe 2020
18 – 19 September, Amsterdam (Noordwijk)

KIDNEY DISEASE

Rituximab for anti-neutrophil cytoplasmic antibodies-associated vasculitis: single-center experience

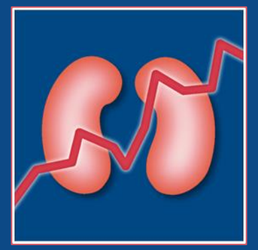

José Agapito Fonseca, Portugal

RITUXIMAB FOR ANTI-NEUTROPHIL CYTOPLASMIC ANTIBODIES-ASSOCIATED VASCULITIS: SINGLE-CENTER EXPERIENCE

José Agapito Fonseca[1], Inês Duarte[1], Joana Gameiro[1], Cristina Outerelo[1], Estela Nogueira[1], Sofia Jorge[1], José António Lopes[1]

[1] Department of Nephrology, Hospital de Santa Maria, Centro Hospitalar e Universitário Lisboa Norte, E.P.E., Lisbon, Portugal

No disclosures

RITUXIMAB FOR ANTI-NEUTROPHIL CYTOPLASMIC ANTIBODIES-ASSOCIATED VASCULITIS: SINGLE-CENTER EXPERIENCE

Introduction Rituximab therapy for severe antineutrophil cytoplasmic antibody–associated vasculitis (AAV) has already been assessed in different randomized controlled trials (RCT), with evidence of non-inferiority compared to oral daily cyclophosphamide for induction of remission. Other regimens combining both rituximab and cyclophosphamide may potentially be superior to rituximab alone for induction of remission. The authors present the single center experience of rituximab use for the treatment of AAV regarding clinical presentation, immunosuppression protocol, outcomes and complications.

Methods Retrospective analysis of clinical records of patients with diagnosis of AAV (de novo or relapse) treated with rituximab in the ward of the Nephrology Department of Centro Hospitalar Universitário Lisboa Norte between January 2015 and December 2019.

The NEW ENGLAND JOURNAL of MEDICINE

ORIGINAL ARTICLE

Rituximab versus Cyclophosphamide for ANCA-Associated Vasculitis

John H. Stone, M.D., M.P.H., Peter A. Merkel, M.D., M.P.H., Robert Spiera, M.D., Philip Seo, M.D., M.H.S., Carol A. Langford, M.D., M.H.S., Gary S. Hoffman, M.D., Cees G.M. Kallenberg, M.D., Ph.D., F. William St. Clair, M.D., Anthony Turkiewicz, M.D., Nadia K. Tchao, M.D.,

The NEW ENGLAND JOURNAL of MEDICINE

ESTABLISHED IN 1812 JULY 15, 2010 VOL. 363 NO. 3

Rituximab versus Cyclophosphamide in ANCA-Associated Renal Vasculitis

Rachel B. Jones, M.R.C.P., M.D., Jan Willem Cohen Tervaert, M.D., Ph.D., Thomas Hauser, M.D., Raashid Luqmani, D.M., F.R.C.P., F.R.C.P.(E.), Matthew D. Morgan, M.R.C.P.

Nephrol Dial Transplant (2019) 34: 63–73
doi: 10.1093/ndt/gfx378
Advance Access publication 14 February 2018

ndt Nephrology Dialysis Transplantation

Long-term follow-up of a combined rituximab and cyclophosphamide regimen in renal anti-neutrophil cytoplasm antibody-associated vasculitis

Stephen P. McAdoo[1,2], Nicholas Medjeral-Thomas[2], Seerapani Gopaluni[3], Anisha Tanna[1,2], Nicholas Mansfield[2], Jack Galliford[1,2], Megan Griffith[1,2], Jeremy Levy[1,2], Thomas D. Cairns[2], David Jayne[3], Alan D. Salama[4] and Charles D. Pusey[1,2]

[1]Renal and Vascular Inflammation Section, Department of Medicine, Imperial College London, London, UK, [2]Vasculitis Clinic, Imperial College Healthcare NHS Trust, London, UK, [3]Department of Medicine, University of Cambridge, Cambridge, UK and [4]Centre for Nephrology, University College London, London, UK

RITUXIMAB FOR ANTI-NEUTROPHIL CYTOPLASMIC ANTIBODIES-ASSOCIATED VASCULITIS: SINGLE-CENTER EXPERIENCE

Results

= 8

4male, 4 female
median age 65.0 ± 12.8 years
average BVAS 22.4 ± 6.8

SCr 4.13 mg/dL ± 3.10 mg/dL (eGFR 17.3 mL/min/1.73 m^2 ± 11.0 mL/min/1.73 m^2)

RPGN on admission = 6 (75.0%)
RRT on admission = 3 (37.5%)

no alveolar hemorrhage on admission

PEX = 3 (37.5%)

RAVE* regimen[1]

[1]1-3 MP 1g iv pulses + RTX 375 mg/m^2 weekly for 4 wk + prednisone 1 mg/kg/d (tapper over 5 mo)

RITUXVAS* regimen[2]

[2]1 MP 1g iv pulse + pred 1 mg/kg/d (tapper to 5 mg over 6 mo) + RTX 375 mg/m^2 weekly for 4 wks + CYC 15 mg/kg iv on wks 1 and 3

CycLowVas* regimen[3]

[3]RTX 1 g (day 0 + week 2) + CYC (day 0, wks 2, 4, 6, 8, 10, the first two 10 mg/kg max 750 mg, last four 500 mg) + pred 1mg/kg/d (max 60 mg), tapper by month 6 to 10mg/day max

* with slight modifications

12-month follow-up

SCr 1.43 ± 0.17 mg/dL (eGFR 35.5 ± 10.7 mL/min/1.73m^2), no patients on RRT

severe infection (n=1, 12.5%)

malignancies (n=1, 12.5%)

death (n=1, 12.5%)

Conclusion In our cohort, patients had higher SCr and higher BVAS than patients from RAVE, RITUXVAS and CycLowVas trials. Additionally we included patients who required renal replacement therapy. Globally, despite the limited number of patients, our experience of rituximab for AAV treatment has produced similar results to those in landmark trials concerning renal recovery, development of severe infection and death rates.

Nephro Update Europe 2020

18 – 19 September, Amsterdam (Noordwijk)

KIDNEY DISEASE

Characterization and renal outcome of biopsy-proven idiopathic focal segmental glomerulosclerosis in a portuguese center - a retrospective cohort study

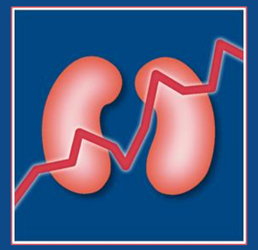

Luisa Costa, Portugal

CHARACTERIZATION AND RENAL OUTCOME OF BIOPSY-PROVEN IDIOPATHIC FOCAL SEGMENTAL GLOMERULOSCLEROSIS IN A PORTUGUESE CENTER - A RETROSPECTIVE COHORT STUDY

Costa L.[1] , Góis M. [2], Viana H. [2] , Nolasco F. [2]
[1] Nephrology Department, Centro Hospitalar Tondela-Viseu, Viseu, Portugal
[2] Nephrology Department, Hospital de Curry Cabral, Lisboa, Portugal

INTRODUCTION:

Focal segmental glomerular sclerosis (FSGS) is a frequently encountered cause of nephrotic syndrome in adults.

The Columbia classification, published in 2004, describes five distinct FSGS variants: collapsing, tip, cellular, perihilar, and not otherwise specified (NOS) and is based on light microscopic patterns.

These histologic variants may have prognostic value.

We aim to analyze the relationship between histological variants of FSGS and renal outcomes in our center.

METHODS:

- Single-center retrospective observational cohort study.
- The study was undertaken at the Centro Hospitalar Tondela-Viseu, Viseu, Portugal.
- The period between January 2013 and July 2018 was selected in the renal biopsies database.
- The keywords “focal”, “segmental” and “glomerulosclerosis” were used within the diagnosis.
- Secondary FSGS were excluded.
- Kidney biopsy specimens were evaluated by two nephro-pathologists - light microscopy and immunofluorescence microscopy.
- Demographic, clinical and laboratory information at the time of each biopsy and follow-up were collected.
- Outcomes were partial and complete remission of the nephrotic syndrome (NS), relapse, steroid-resistant and steroid-dependent (defined accordingly do KDIGO), and renal failure.
- The chi-square independence test was used to evaluate if two categorical variables were related.

RESULTS:

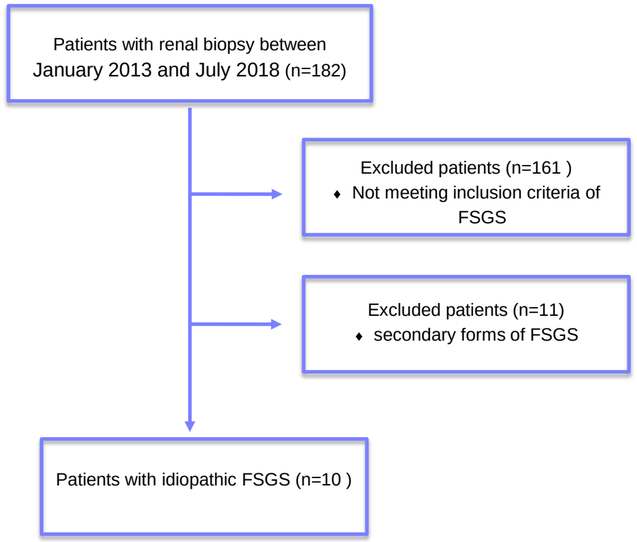

Graphic 1 - Flow diagram of patient selection process

	NOS	Peri-hilar	Tip	Collapsing	Cellular	TOTAL
Gender						
Male	1	1	2	0	0	4
Female	1	2	3	0	0	6
Mean age (years)	60,5	68,3	48,2	-	-	56,7

Table 1 - Patients characteristics.

Although the mean age of peri-hilar variant was 68,3 years and tip variant was 48,2 years, there was no statistically significant difference between the two. (p=0.251)

	NOS	Peri-hilar	Tip	TOTAL (N=10)
RENAL INDICES				
Proteinúria (g/day)				
< 0,15	0	0	0	0
0,150-3,5	2	1	1	4
>3,5	0	2	4	6
NS	1	2	4	7
CKD	0	1	1	2
CKD stage				
1	0	0	0	0
2	0	1	1	2
3	0	0	0	0
4	0	0	0	0
5	0	0	0	0
AKIN Severity				
1	0	1	0	1
2	0	1	0	1
3	0	0	0	0
HISTOLOGIC FINDINGS				
Glomeruli				
Global glomerulosclerosis (%)	6,5	7	5	5,1(mean, %)
Interstitial fibrosis (Presence of)	1	2	4	7
Tubules (Presence of)				
Acute tubular necrosis	0	2	1	3
Presence of tubular atrophy	1	2	3	6
Arteriosclerosis and arteriolar hyalinosis				

Table 2 - Renal indices and histologic findings of focal segmental glomerulosclerosis variants. NS: Nephrotic syndrome, CKD: chronic kidney disease

	NOS	Peri-hilar	Tip	TOTAL
Treatment				
Steroids (1mg/Kg/day)	1	2*	4	7
Renal outcomes				
Response to steroids				
Complete remission	1	1	1	3
Partial remission	0	0	1	1
Steroid resistant	0	0	2	2
Renal survival (%)				
1-year	100	100	100	100
2-year	100	100	75	87,5

Table 3 - Treatment and renal outcomes of focal segmental glomerulosclerosis variants.*One patient died shortly after the diagnosis.

CONCLUSIONS:

Seven patients presented with NS and were treated with steroids, 3 had complete remission (1 tip variant, 1 peri-hilar and 1 NOS variant), 1 partial remission (tip variant) and 2 were steroid-resistant (2 tip variants). One patient have died shortly after diagnosis.

One year renal survival was 100% and 2 year renal survival was 87,5%.

Since our sample was small, it was not possible to demonstrate a relationship between the histologic variant of FSGS and the form of presentation or renal outcome.

Nephro Update Europe 2020

18 – 19 September, Amsterdam (Noordwijk)

KIDNEY DISEASE

What water should I drink Doc?

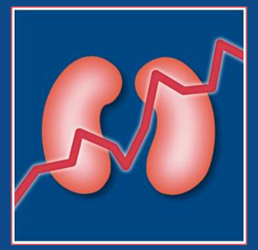

Rui Silva, Portugal

What water should I drink Doc?

R. Silva*[1], J. Silvano*[1], M. Relvas*[1], N. Marques*[1], F. Ferreira*[1], A. Beco*[1], S. Marques*[2]

*[1] Centro Hospitalar de São João, Nephrology Department (Porto, Portugal)
*[2] Hospital de Braga, Nephrology Department (Braga, Portugal)

INTRODUCTION

- Normal anion gap metabolic acidosis is common in CKD.
- Metabolic acidosis correction improves bone health, nutritional status and progression of CKD.
- KDIGO 2013: serum bicarbonate concentration ≥ 22mEq/L; usually accomplished with sodium bicarbonate supplements.
- Eating fruits, vegetables and reducing animal-based protein intake can be helpful.

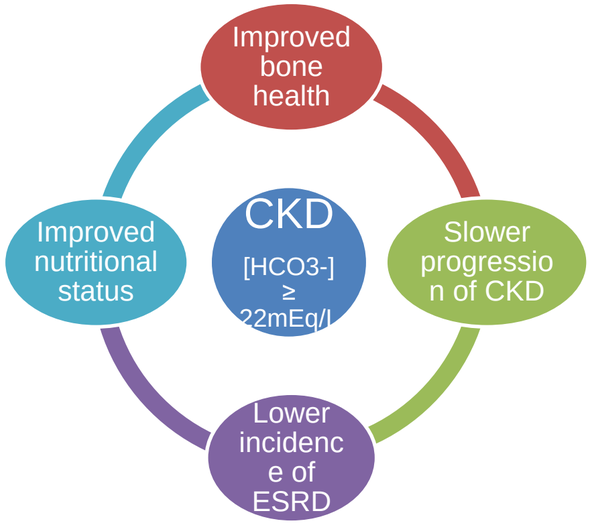

Figure 1. Advantages of correcting CKD metabolic acidosis

OBJECTIVES

- Identify the most bicarbonate-rich bottled water(s) to correct metabolic acidosis in CKD.

MATERIALS AND METHODS

- Sample: 32 Portuguese bottled waters.
- Volume of water to administer 0.5 or 1mEq of bicarbonate/kg/day = (weight x 30.5 or 61)/water HCO3- concentration (mg/L).

RESULTS

Table 1. Descriptive statistics

Sample	n = 32
Sparkling waters	11 (31%)
Median [HCO3-]	155 mg/L (IQR 354,3)
Maximum [HCO3-]	2100 mg/L (Frize®)
Minimum [HCO3-]	2,6 mg/L (Caldas de Penacova®)

Table 2. Volume of water to provide 0,5 – 1 mEq HCO3/kg/day

Bicarbonate pill	(-)	HCO3- mg	Na+ mg	Cl-	Doses 0,5 mEq/day	Doses 1 mEq/day
NaHCO3 1g tid	(-)	2250	750	(-)	1	2

Water	pH	HCO3- mg/L	Na+ mg/L	Cl- mg/L	Volume 0,5 mEq/day(L)	Volume 1 mEq/day(L)
Frize®	(-)	2100	635	122	1,0	2,0
Pedras Salgadas®	6,1	1983	577	30	1,1	2,2
Vidago®	6,2	1972	621	31	1,1	2,2

Graphic 1. Water HCO3 concentration in mg/L

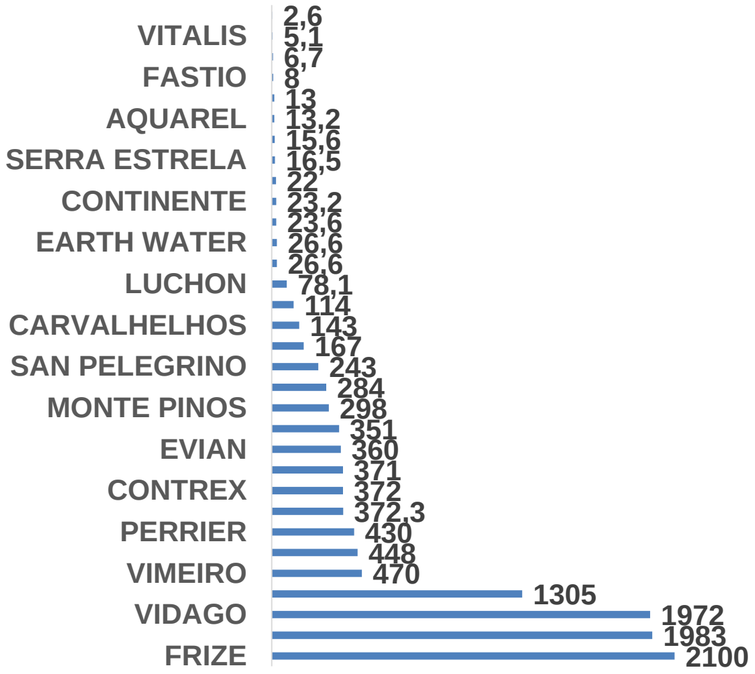

- CKD patients with chronic metabolic acidosis could benefit from drinking water brands such as Frize®, Pedras Salgadas® or Vidago®.
- In France, CKD patients are advised by some Nephrologists to drink *Vichy®*: bicarbonate 3g/L.
- Advantages: avoid adding bicarbonate pills to patients with a high pill burden.
- Disadvantages: possible fluid retention, hyponatremia, as well as the cost of bottled water compared to tap water.

Shah SN, Abramowitz M, Hostetter TH, Melamed ML. Serum bicarbonate levels and the progression of kidney disease: a cohort study. American journal of kidney diseases : the official journal of the National Kidney Foundation. 2009;54(2):270-7.
de Brito-Ashurst I, Varagunam M, Raftery MJ, Yaqoob MM. Bicarbonate supplementation slows progression of CKD and improves nutritional status. Journal of the American Society of Nephrology : JASN. 2009;20(9):2075-84.
Chapter 3: Management of progression and complications of CKD. Kidney international supplements. 2013;3(1):73-90.
Goraya N, Wesson DE. Management of the Metabolic Acidosis of Chronic Kidney Disease. Advances in chronic kidney disease. 2017;24(5):298-304.

Nephro Update Europe 2020
18 – 19 September, Amsterdam (Noordwijk)

KIDNEY DISEASE

An unusual case of acute kidney and liver injury

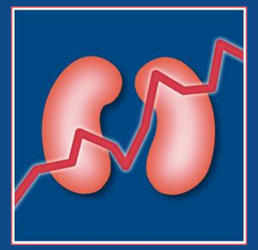

Rui Silva, Portugal

An unusual case of acute kidney and liver injury

R. Silva*[1], J. Silvano*[1], M. Relvas*[1], N. Marques*[1], F. Ferreira*[1], A. Beco*[1], A. Praça*[1]

*[1] Centro Hospitalar de São João, Nephrology Department (Porto, Portugal)

INTRODUCTION

Amatoxin poisoning following mushroom ingestion (*ex. Amanita phalloides*) presents in 3 phases: phase I (dysentery 6-24h after ingestion), phase II (emergence of hepatitis 24-36h after ingestion) and phase III (acute liver failure, often accompanied by acute kidney injury).

CASE REPORT

ID: Male, 74 years old.

Past medical history: CKD 3a diabetic nephropathy (sérum Cr 1,3 mg/dL) | Hypertension | Prostatic adenocarcinoma – radical prostatectomy in 2005 and radiotherapy in 2013 | Colon adenocarcinoma - sigmoidectomy and chemotherapy in 2007.

Medication: furosemide 40mg id, lisinopril/HCTZ 20+12,5mg id, AAS 100mg id, metformine 1g bid, sinvastatine 40mg id, alopurinol 100mg id, omeprazol 20mg id

Case report: Presented at the emergency room (ER) complaining of colic abdominal pain, vomiting and profuse diarrhea for the past four days. Dehydrated, hypotensive (84/35 mmHg), with jaundice. Maintained diuresis. Twenty-four hours earlier, his wife, 74 years old, had been admitted to the ER with overlapping findings. Both consumed wild mushrooms 24h before symptoms onset

Physical examination: Dehydrated, hypotensive (84/35 mmHg), jaundice. Maintained diuresis.

Hemograme	**Hb** 12,7 g/dL **Leucócitos** 7720/uL **Plaquetas** 179,000/uL
Blood chemistry	**Albumina** 35,7 g/L **AST** 1262 U/L **ALT** 2500 U/L **GGT** 24 U/L **FA** 66 U/L **BT** 2,69 mg/dL **BD** 1,72 mg/dL **Amilase** 29 U/L **Lipase** 28 U/L **DHL** 1069 U/L **CK** 61 U/L **Amónia** 112 umol/L **Gli** 220 mg/dL **U** 156 mg/dL **Cr** 5,22 mg/dL **Ca^{2+}** 0,92 mmol/L **Pi** 5,6 mg/dL **Mg^{2+}** 0,78 mmol/l **Na^{+}** 139 mEq/L **K^{+}** 3,9 mEq/L **Cl^{-}** 107
ABG (FiO2 0,21%)	**pH** 7,32 **pCO2** 32 **pO2** 88 **$HCO3^{-}$** 16 **Na^{+}** 137 **Cl^{-}** 104 **K^{+}** 3,9 **AG** 17 **Lact** 2,7
Coagulation	**aPTT** 31,6s **TP** 18s **Fib** 310 mg/dL **P&P** 0,60
Viral serologies	**VIH**, **VHB**, **VHC** non-reactive.
Abdominal and kidney US	No liver or kidney changes.
Urine	**Erythrocytes** 23,1/uL + 1-2 **granular casts**/CGA

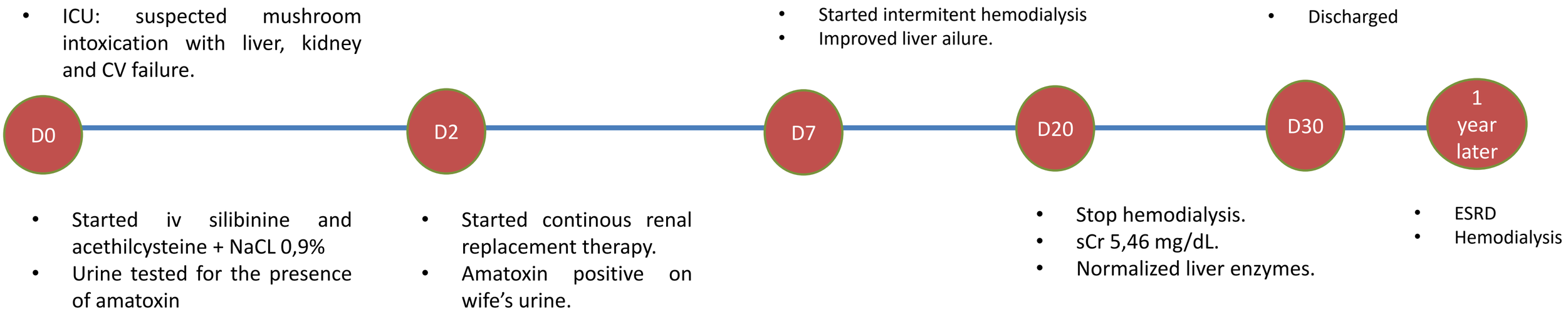

Conclusion

Amatoxin containing mushrooms is a rare cause of acute kidney injury. The proposed mechanisms of renal injury by amatoxin are: direct tubular nephrotoxicity, hypovolaemia secondary to dysentery or liver failure with associated multiorgan dysfunction. The identification of amatoxin in the urine is more likely in the first 36 hours, being unlikely after 4 days of ingestion. The detection of α-amanitin in the wife's urine, as well as the epidemiological context and identical presentation, support the diagnosis of mushroom poisoning in both.

Nephro Update Europe 2020

18 – 19 September, Amsterdam (Noordwijk)

KIDNEY DISEASE

The grey area between operational tolerance and overt rejection

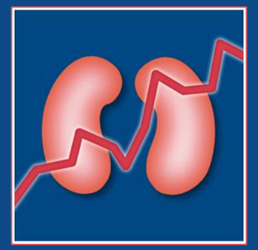

Rui Silva, Portugal

The grey area between operational tolerance and overt rejection

R. Silva*[1], M. Relvas[*1], J. Silvano[*1], N. Marques[*1], F. Ferreira[*1], A. Beco[*1], A. Nunes[*1], M. Bustorff[*1], S. Sampaio[*1]

[*1] Centro Hospitalar de São João, Nephrology Department (Porto, Portugal)

INTRODUCTION

- Operational tolerance in kidney transplantation: serum creatinine [sCr] < 1,7 mg/dL and proteinuria < 1 g/day in the absence of immunosuppressive drugs for at least one year.
- Presence of HLA donor specific antibodies (DSAs) is common.

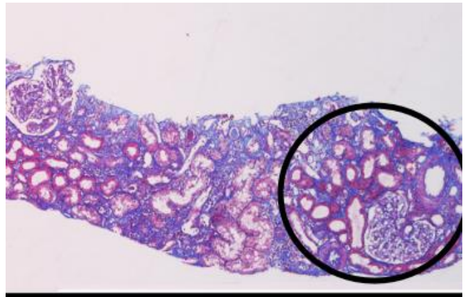

Image 1 (PAS): Fibrosis

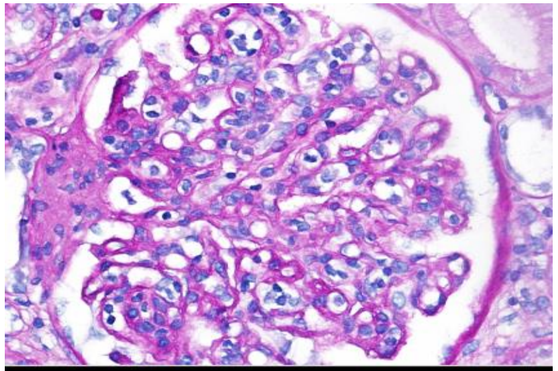

Image 2 (HE): Glomerulitis

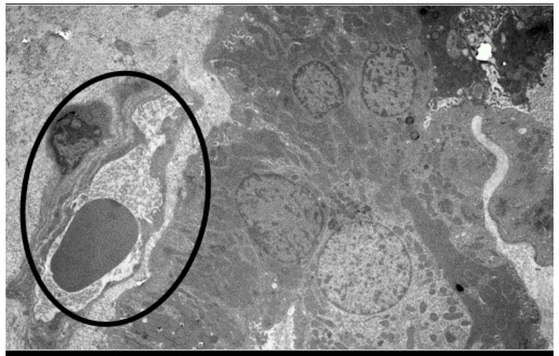

Image 3 (EM): Chronic humoral rejection – peritubular capillary basement membrane multilayering

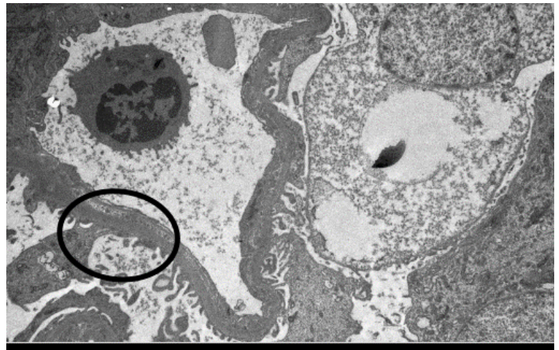

Image 4 (EM): Chronic humoral rejection – subendothelial expansion

CASE REPORT

- 53-year-old female; kidney transplant in September 2007. Shortly after the transplant, there was an episode of biopsy proven acute Ib T cell mediated rejection, successfully treated with thymoglobulin and methylprednisolone.
- Maintenance immunosuppression (IS): tacrolimus, mycophenolate and prednisolone. Lost to follow-up in 2011, at the time with a serum creatinine (sCr) of 0,8 mg/dL, ceasing IS.
- Admitted eight years later for acute graft pyelonephrtis, under no IS, with a sCr of 1.04 mg/dL and no proteinuria.
- Four *de novo* HLA DSAs (A34 – 10688 MFI, B45 – 5833 MFI, DQ7 – 24990 MFI, DQ4 – 2571 MFI), with anti-DQ7 as the sole C1q fixing antibody.
- Crossmatch by flow cytometry using donor cells showed T and B cell positivity.
- Slight deterioration of graft function sCr of 1,4 mg/dL led to graft biopsy in June 2019. Findings were compatible with chronic active antibody-mediated rejection (ABMR). Positive C4d (+++).
- At this point, previous maintenance IS was reintroduced. Furthermore, the patient was treated with intravenous (IV) immunoglobulin (Ig).
- The patient has since been kept solely under maintenance IS, with a current serum creatinine of 1,25 mg/dL (June 2020).

- Operational tolerance in kidney transplantation is characterized by a stable graft function (sCr < 1,7 mg/dL and proteinuria < 1 g/day) in the absence of immunosuppressive drugs for at least one year.

- However, simultaneous presence of donor specific antibodies is common and sCr is a poor surrogate of early lesions.

- Consequently, subclinical rejections will meet operational tolerance criteria as long as sCr remains stable.

- Kidney surveillance biopsies may be useful to rule out subclinical conditions associated with shortened graft survival in operational tolerant patients.

Nephro Update Europe 2020
18 – 19 September, Amsterdam (Noordwijk)

DIALYSIS

Possible value of miRNAs in cardiac remodeling in dialysis patients

Anastasiia Rind, Russian Federation

Possible value of miRNAs in cardiac remodeling in dialysis patients

Rind A.R.[1], Essayan A.M.[1], Kaukov I.G.[1], Zaraiskii M.I.[2]

[1]Department of nephrology and Dialysis, I.P.Pavlov First Saint-Petersburg State Medical University, Saint-Petersburg, Russia

[2]Department of clinical laboratory diagnostics, I.P.Pavlov First Saint-Petersburg State Medical University, Saint-Petersburg, Russia

The authors declare that have no relevant or material financial interests that relate to the research

Objective: to analyze the relationship between the level of miRNA-21, miRNA-126 and indicators of echocardiography and lipid metabolism in dialysis patients.

Materials and methods:

- 40 patients with chronic kidney disease receiving treatment with dialysis were examined
- 18 on hemodialysis, 22 on peritoneal dialysis.
- All subjects measured the level of expression of miRNA-21 and miRNA-126 in blood plasma by PCR, performed echocardiography.
- For statistical processing of the results, the Spearman rank correlation was used.

Results: LVML positively correlated with miRNA-21 in all patients. LVMI directly correlated with miRNA-21 in all patients. No correlation was found between the level of miRNA-126 and indicators of heart remodeling. The level of microRNA-21 negatively correlated with the value of total cholesterol and the level of low density lipoproteins. Both miRNA-21 and miRNA-126 inversely correlated with serum total cholesterol. However, low miRNA-21 values were associated with higher levels of low density lipoproteins, while miRNA-126 negatively correlated with high density lipoproteins.

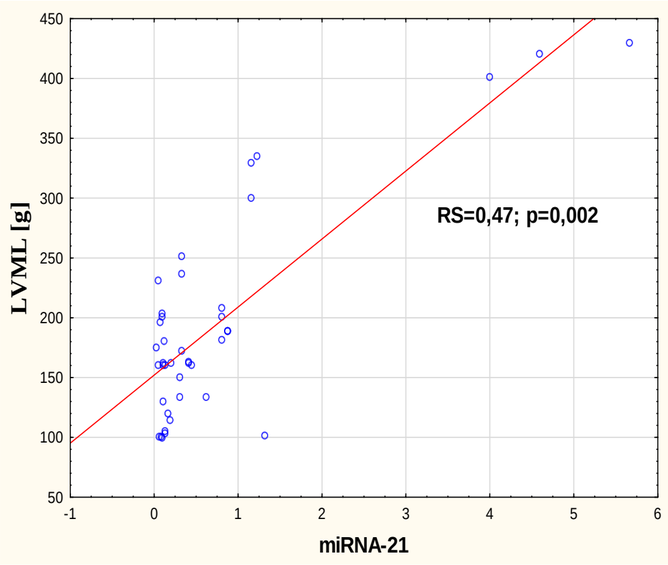

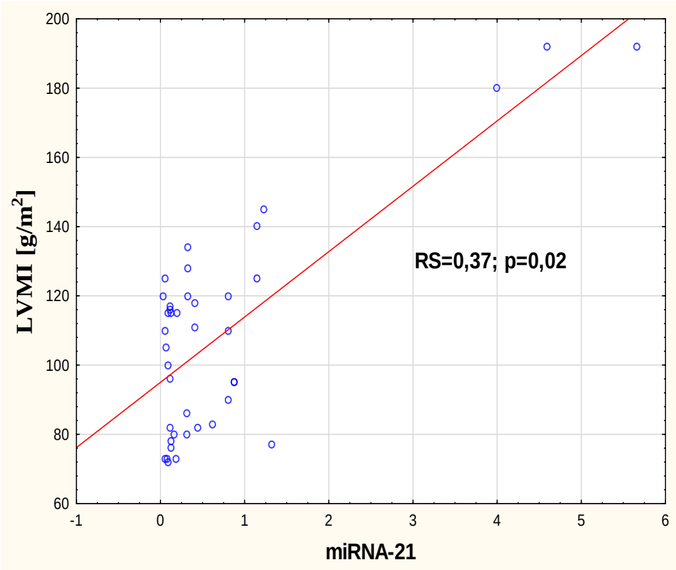

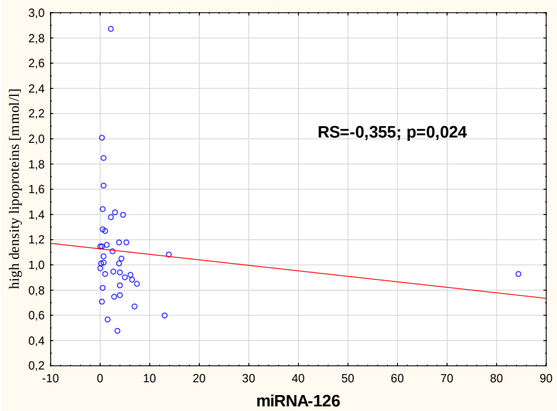

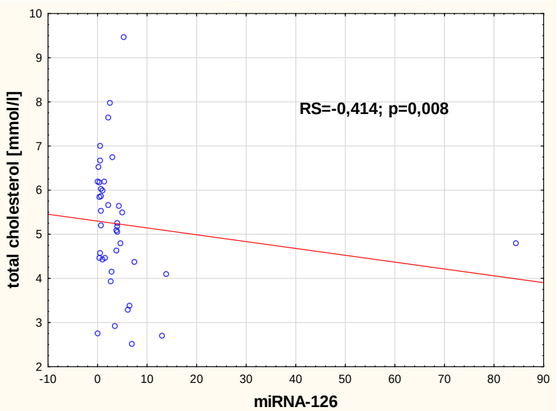

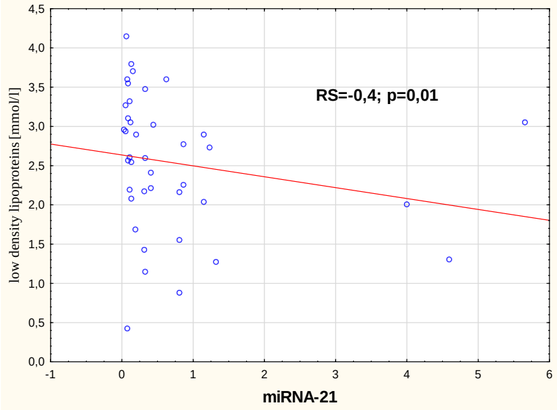

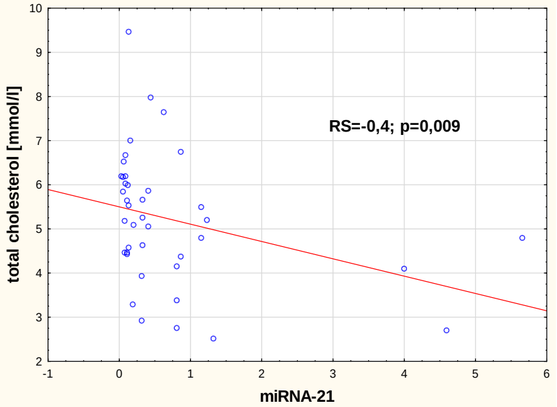

Conclusions: High level of expression of miRNA-21 in blood plasma is positively associated with the development of left ventricular myocardial hypertrophy in patients receiving renal replacement therapy with dialysis. Indicators of miRNA expression also reflect the state of lipid metabolism in dialysis patients.

Nephro Update Europe 2020
18 – 19 September, Amsterdam (Noordwijk)

DIALYSIS

OUTCOMES OF ELDERLY PATIENTS STARTING HEMODIALYSIS

Patrícia Alves, Portugal

OUTCOMES OF ELDERLY PATIENTS STARTING HEMODIALYSIS

Alves, P; Góis, M; Sousa, J; Nolasco, F.

Nephrology Department. Centro Hospitalar Lisboa Central. Portugal

OUTCOMES OF ELDERLY PATIENTS STARTING HEMODIALYSIS – A retrospective observational cohort

Hemodialysis of elderly patients has become the rule rather than the exception.

What are the clinical outcomes of elderly patients starting hemodialysis?

Can their comorbidities predict unfavorable outcomes?

- Retrospective, observational cohort including **patients aged ≥75 years incident in hemodialysis**
- **12 month follow-up**
- PRIMARY OUTCOME: **All cause mortality**
- SECONDARY OUTCOME: Deterioration of performance status
- Patient characteristics at initiation of dialysis were summarized
- **Charlson Comorbidity Index was evaluated as a predictor of 12-month mortality** via logistic regression

OUTCOMES OF ELDERLY PATIENTS STARTING HEMODIALYSIS – Results and Conclusion

77 patients, mean age of 81,6 years (SD 4.3). Multiple comorbidities (mean Charlson Comorbidity Index 8.23, SD 1.9)
23 of them needed assistance with daily living and 7 were institutionalized.

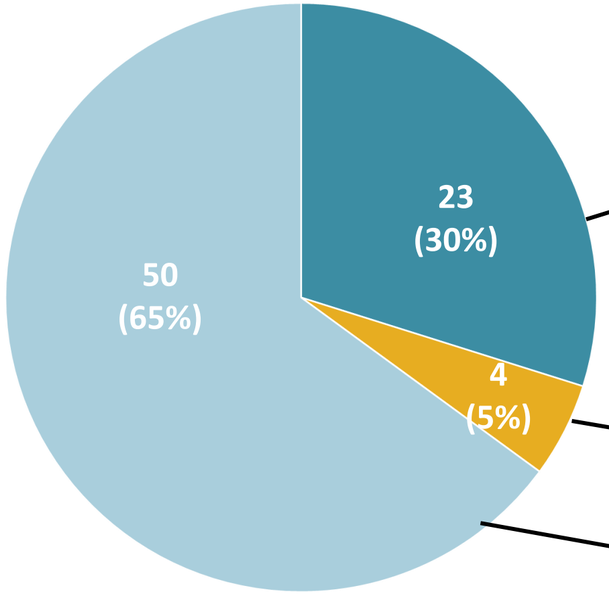

23 patients (30%) died.
They were more likely to be **older**, to have initiated hemodialysis with a **catheter**, to have needed **assistance with daily living**, to have been **institutionalized** and to **had lower albumin**. They had a **higher Charlson Comorbidity Index score** (p=0.01), binary logistic regression identified **Charlson Comorbidity Index as an independent predictor of mortality at 12 months** (odds ratio 1.424, p=0.014).

4 patients (5%) had significant deterioration of performance status

50 patients (65%) were alive with no performance status deterioration at 12 months

Other factors, other than old age, should be evaluated when predicting the outcome of an elderly patient starting hemodialysis.

Nephro Update Europe 2020

18 – 19 September, Amsterdam (Noordwijk)

OTHER

USEFULNESS OF PROTOCOL RENAL ALLOGRAFT BIOPSIES

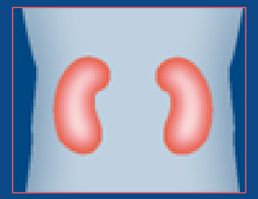

Patrícia Alves, Portugal

USEFULNESS OF PROTOCOL RENAL ALLOGRAFT BIOPSIES

Alves, P; Góis, M; Vieira, M; Nolasco, F.

Nephrology Department. Centro Hospitalar Lisboa Central. Portugal

USEFULNESS OF PROTOCOL RENAL ALLOGRAFT BIOPSIES – A retrospective observational cohort

Performing early renal allograft protocol biopsies may be clinically useful in identifying early acute rejection, though, this approach is not consensual.

We aim to assess its safety and efficacy in improving medium-term outcomes of renal allograft.

- Retrospective, observational cohort including **adult kidney transplant recipients who underwent protocol biopsy**
- Patients with a clinical indication for biopsy were excluded
- Adequate treatment was employed when subclinical rejection or borderline changes were present
- Medium-term outcomes of patients with subclinical rejection or borderline changes on protocol biopsy (group 1) were compared to those without immunological changes (group 2)

USEFULNESS OF PROTOCOL RENAL ALLOGRAFT BIOPSIES – Results and Conclusion

96 patients, mean follow-up of 65 months.

Protocol biopsy was performed, on average, 2 weeks after kidney transplant, with no major complications.

8 patients (8,3%) had signs of **SUBCLINICAL REJECTION**

5 patients (5,2%) had **BORDERLINE CHANGES**

} GROUP 1 ⋯⋯→ EARLY TREATMENT

83 patients (86,5%) had **NO** immunological changes } GROUP 2

Age, gender, race and number of HLA-DR antigen mismatches were similar between groups.

Basiliximab (vs. antithymocyte globulin) was associated with increased **incidence of subclinical rejection** (p=0,01).

At the end of follow-up there was **NO DIFFERENCE** between group 1 and group 2 in terms of number of subsequent **rejection episodes**, **glomerular filtration rate**, **graft survival or mortality**.

Patients with subclinical rejection and borderline changes had similar medium-term outcomes to those without immunological changes on protocol biopsy, thanks to early treatment.

Nephro Update Europe 2020

18 – 19 September, Amsterdam (Noordwijk)

DIALYSIS

Ferritin and SARS-CoV2 infection in hemodialysis: a single-center experience

Rita Calça, Portugal

Ferritin and SARS-CoV2 infection in hemodialysis: a single-center experience

Sousa LL[1], Calça R[1], Camacho C[2], Fernandes M[2], Faria C[2], Santos AM[2], Fonseca C[2], Mansinho K[3]

[1] Nephrology Department, Centro Hospitalar de Lisboa Ocidental, Lisbon, Portugal

[2] Internal Medicine Department, Centro Hospitalar de Lisboa Ocidental, Lisbon, Portugal

[3] Infeccious Diseases Department, Centro Hospitalar de Lisboa Ocidental, Lisbon, Portugal

INTRODUCTION

Several studies have been conducted in an effort to discover clinical and laboratorial markers of disease severity or mortality of COVID-19 in the general population. One of such markers is ferritin, which is not only involved in iron metabolism, but is also an important immune mediator. In many studies, there was an association between serum ferritin levels and severity or mortality of COVID-19. Although there are many papers focusing on the general population, data regarding markers of outcome in chronic hemodialysis patients, a population with an intrinsically elevated risk, is scarce. Thus, we aimed to evaluate the importance of serum ferritin in hemodialysis patients with COVID-19.

METHODS

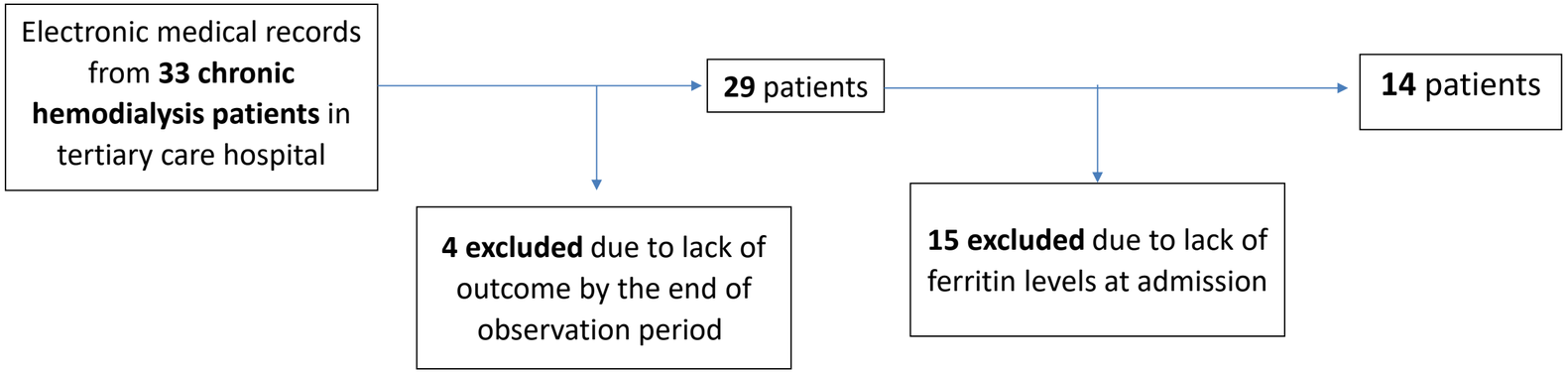

RESULTS

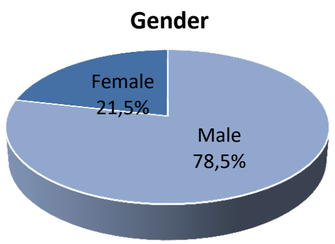

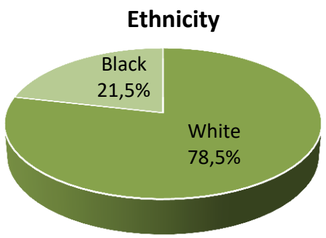

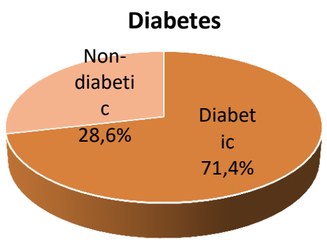

	Age (years)	Ferritin (ng/mL)
Median	71	1605
Minimum	27	257
Maximum	93	4509

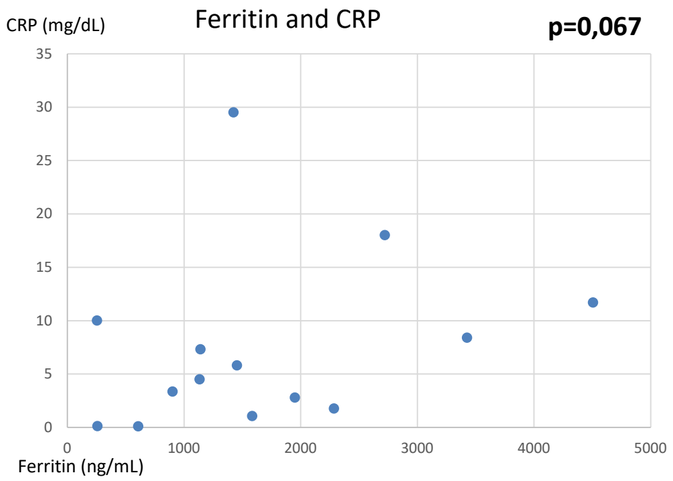

There was a trend between elevation of ferritin and C-Reactive Protein but did not reach statistical significance.

	Ferritin value
Hypoxemia (PaO_2/FiO_2 <300)	p=0,589
MEWS > 3	p=0,385
EWS COVID-19 > 5	p=0,158

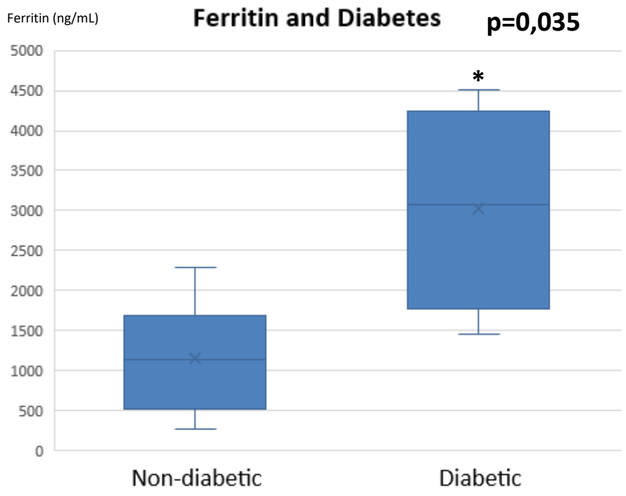

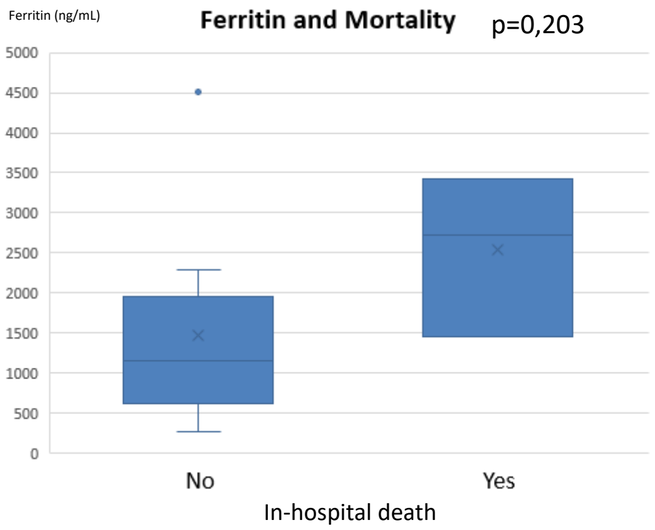

CONCLUSION

In contrary to what has been described in many studies for the general population, we found **no association between ferritin and markers of disease severity or mortality.** Interestingly, we found **significantly higher serum ferritin in diabetic patients**, which may not be only explained by lack of glycemic control and could be of interest for future research.

Nephro Update Europe 2020
18 – 19 September, Amsterdam (Noordwijk)

OTHER

Severity scores utility in hemodialysis patients with SARS-CoV-2 infection

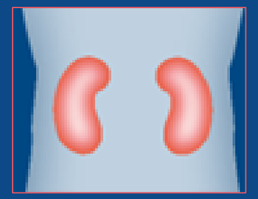

Rita Veríssimo, Portugal

Severity scores utility in hemodialysis patients with SARS-CoV-2 infection

Verissimo R (1), Francisco D (1), Brito C (2), Dionisio A (2), Mesquita T (2), Mendes A (1), Mansinho K (3), Fonseca C (2), Machado D (1)

1 – Nephrology Department, Centro Hospitalar Lisboa Ocidental, Lisboa, Portugal
2 – Internal Medicine Department, Centro Hospitalar Lisboa Ocidental, Lisboa, Portugal
3 – Infectious Diseases Department, Centro Hospitalar Lisboa Ocidental, Lisboa, Portugal

Rationale

- The clinical spectrum of SARS-CoV-2 infection ranges from asymptomatic to severe pneumonia.
- Previous chronic kidney disease (CKD) is associated with worse outcomes.
- We aim to investigate the utility of early warning score for 2019-nCov infected patients (EWS 2019 nCoV) and modified early warning score (MEWS) in hemodialysis patients.

Methods

Study Design

- Retrospective
- Unicentric
- Hemodialysis adult patients
- Admitted in a hospital ward
- Laboratory confirmed SARS CoV2 infection

From March 27th to July 27th

Demographic, Clinical and laboratory data were extracted from clinical records

EWS 2019 nCoV and MEWS scores were calculated and scores of survivors were compared to non survivors (using T-student test, Mann-Whitney U or exact Fisher test)

The main outcome was the ability of these scores to predict in-hospital mortality

Results

Population (n=29)

- 62.1% were male
- Median age (IQR) of 74 years (61.5-80.5)
- Median time in HD was 54 months (17.25-83.5)
- Besides CKD: 37.9% had one more comorbidity; 34.5% two comorbidities; 27.6% more than three
- 20.6% of the cases were nosocomial infections

Outcomes

- 13.8% had to be transferred to ICU
- 27.3% mortality

Severity scores

- Median of MEWS score was 2 (1-3)
- Median of EWS 2019 nCoV 7 (4.5-10.5)
- Group of survivors *vs* the non survivors had:
  - Higher MEWS score
    - Median 2 (1-3) vs 3 (2-3.5), *p= 0.029*
  - Higher EWS 2019 nCoV score
    - Median 5.5 (3.25-8.75) vs 9 (7.5-13.5), *p= 0.013*

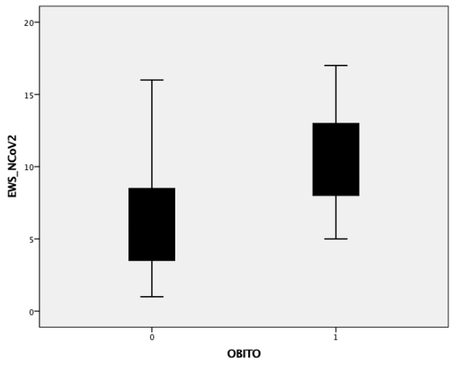

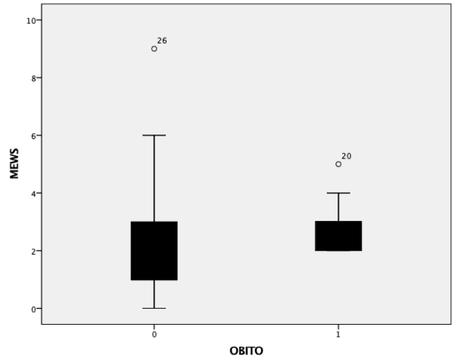

Conclusions

- Both severity scores showed ability to predict in-patient mortality in hemodialysis patients affected by Covid 19 disease.
- These may be important tools to recognize patients that can benefit from closer surveillance ICU admission.
- Studies with larger population will confirm the usefulness of these scores in this particular group of patients.

Nephro Update Europe 2020
18 – 19 September, Amsterdam (Noordwijk)

DIALYSIS

D-dimers value in COVID-19 patients on chronic hemodialysis

Eunice Cacheira, Portugal

D-dimers value in COVID-19 patients on chronic hemodialysis

A single center study

Eunice Cacheira[1], Rita Veríssimo[1], Andreia Machado[2], Rita Ribeiro[2], Teresa Mesquita[2], Kamal Mansinho[3], Cândida Fonseca[2]

[1] Nephrology Department, Hospital Santa Cruz, Centro Hospitalar Lisboa Ocidental, PORTUGAL
[2] Internal Medicine Department, Hospital São Francisco Xavier, Centro Hospitalar de Lisboa Ocidental, PORTUGAL
[3] Infectious Diseases Department, Hospital Egas Moniz, Centro Hospitalar de Lisboa Ocidental, PORTUGAL

D-dimers value in COVID-19 patients on chronic hemodialysis

Introduction: Since SARS-CoV-2 outbreak, clinical, laboratorial and radiological findings have been studied as outcome predictors. Elevated D-dimers are associated with severe COVID-19. On the other hand, ESRD hemodialysis patients have significantly higher D-dimers levels than non-HD patients, which limit its use. We aim to evaluate the prognostic significance of D-dimers on SARS-CoV-2 infected patients on chronic hemodialysis.

Methods: We report a retrospective single-center study including all inpatients on chronic hemodialysis with SARS-CoV-2 RT-PCR positive test admitted from 15th March to 31st July 2020. Demographic, clinical and laboratory data were assembled. SPSS software was used for statistical analysis. The main outcome was the ability of D-dimers to predict COVID-19 mortality in hemodialysis patients with COVID-19 disease. Secondary outcomes evaluated the association of D-dimers with ICU admission and MEWScore.

D-dimers value in COVID-19 patients on chronic hemodialysis

Results: From 33 patients admitted, 21 had D-dimers evaluation on admission, with a median value of 1811ng/dL (597-27891). 71.4% of the patients were male, with mean age of 69.7 years (±15.2). Besides ESRD, 1/3 of the patients had heart failure and 4 had cancer. D-dimers on hemodialysis patients had no significant association with COVID-19 mortality or ICU admission. D-dimers were significantly higher among patients with MEWS ≥ 5 [median IQR 4224.5ng/mL (2432-18997) vs 1171ng/mL (972-1950.5), p=0.036].

Conclusion: No association was established between D-dimers levels and COVID-19 mortality or ICU admission among hemodialysis patients, which differs from the non-HD population. However, it did correlate with a high MEWS. Larger studies are required to better characterize the predictors of COVID-19 disease outcomes among ESRD patients.

Nephro Update Europe 2020
18 – 19 September, Amsterdam (Noordwijk)

OTHER

Clinical presentation and prognosis of hemodialysis patients infected with SARS-CoV2

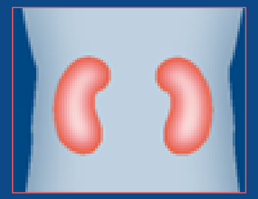

Ana Catarina Mateus, Portugal

Clinical presentation and prognosis of hemodialysis patients infected with SARS-CoV2

Mateus, C. [1]; Veríssimo, R. [1]; Pimenta, G. [1]; Martins, C. [1]; Branco, P. [1], Mendes, A. [1]; Mesquita, T. [2]; Mansinho, K. [3]; Fonseca, C. [2]

1 - Centro Hospitalar Lisboa Ocidental, Hospital de Santa Cruz, Department of Nephrology, Lisbon, Portugal
2 - Centro Hospitalar Lisboa Ocidental, Hospital de Santa Cruz, Department of Internal Medicin, Lisbon, Portugal
3 - Centro Hospitalar Lisboa Ocidental, Hospital de Santa Cruz, Department of Infectious Diseases, Lisbon, Portugal

Racionale

In 2020, severe acute respiratory syndrome coronavirus 2 (SARS-CoV-2) infection spread around the world.

There are increasing data about clinical presentation and prognosis in general population, but infection in hemodialysis patients is still poorly characterized.

Methods

Retrospective, observacional

Unicentric

CENTRO HOSPITALAR DE LISBOA OCIDENTAL, E.P.E.

March 27th - July 27th, 2020

Maintenance hemodialysis patients

Laboratory-confirmed SARS-CoV-2 infection

Admitted to the hospital

Demographic, clinical and laboratory data were extracted from medical records.

Univariable logistic regression methods were used to evaluate risk factors associated with mortality.

Results

Population:

n = 33 hemodialysis patients

61% male

Median age of 73 years (IQR 61-80.5)

Median time in hemodialysis of 54 months (IQR 18.2-88.8)

64% had arteriovenous fistula as vascular access

21% of the SARS-CoV-2 infections were nosocomial

At admission:

18% assymptomatic disease

Fever 58%

Dyspnea 33%

Cough 46%

Diarrhea 12%

58% pathologic changes in chest x-ray
36% of which bilateral

Median leukocyte count 4.8×10^9 (IQR 3.75-6.9)

Median lymphocyte count 820×10^9 (IQR 585-1220)

C reactive protein 6.4 mg/dl (IQR 1.53-12.25)

Outcomes:

12% admitted in the **ICU**

27% died

Predictors of mortality at admission (univariable analysis):

The need for supplemental oxygen ($p = 0.007$)

Higher leukocyte count ($p = 0.01$)

Higher C reactive protein ($p = 0.027$)

Nosocomial infection ($p = 0.01$)

Conclusion

Mortality between maintenance hemodialysis patients was high.
Nosocomial infection was associated with poor prognosis.
Larger studies are needed to validate our results.

Nephro Update Europe 2020
18 – 19 September, Amsterdam (Noordwijk)

KIDNEY DISEASE

ANCA-associated vasculitis (AVV) and IgG4-related disease (igg4-RD)

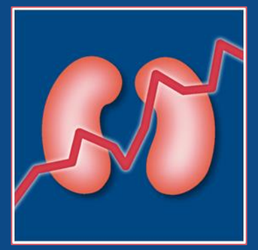

Ines Sala, Portugal

ANCA-ASSOCIATED VASCULITIS (AVV) AND IGG4-RELATED DISEASE (IGG4-RD)

- AN OVERLAP SYNDROME OR TWO DISTINCT DISEASES?

Sala, I[1]; Freitas, J[1]; Oliveira, JP[1]; Tavares, JM[1]; Silva, F[1]; Santos, S[1]; Castro, A[1]; Campos, A[1]; Santos, J[1]; Cabrita, A[1]

[1]Nephrology Department, Centro Hospitalar Universitário do Porto

83-year-old with a past history of pulmonary tuberculosis and hypertension. Presented with:

Anorexia, weight loss and fatigue in the last 6 months:

At admission, the examination was unremarkable. The blood tests showed:

→ **Rapidly progressive kidney disease** (sCr 4.1<1,5<0,98mg/dL),

→ **Severe anemia** (Hb 7.8g/dL) and a **systemic acute inflammatory response** (C-reactive-protein 100mg/dL and ERS of 80mm).

→ **Urine exam** had **non-nephrotic proteinuria** (2.1g/g creatinine). **Urinary sediment** had **erythrocyturia and leukocyturia** (10-25 WBCs and RBCs/HPF.**)**

→ **Immunological study** revealed a **high serum IgG** (1714 mg/dL) - subclasses IgG1 elevated and IgG4 on ULN[1] and **myeloperoxidase-ANCA positivity** (**66U/mL**).

On light microscopy kidney biopsy showed a **severe interstitial lymphoplasmacytic infiltrate and cellular crescentic lesions (5/8).** Immunofluorescence was negative. Immunohistochemical study showed **more than 30 IgG4 positive plasmocytes** per large magnification field.

Crescentic pauci-immune glomerulonephritis (GN) and IgG4 interstitial infiltrate

The patient started **corticotherapy** (pulses of 500mg/day of methylprednisolone, then oral prednisolone 1mg/Kg/day) as well as 375/m^2 **rituximab** with clinical and analytical improvement (stabilization of sCr 2,5mg/dL).

A

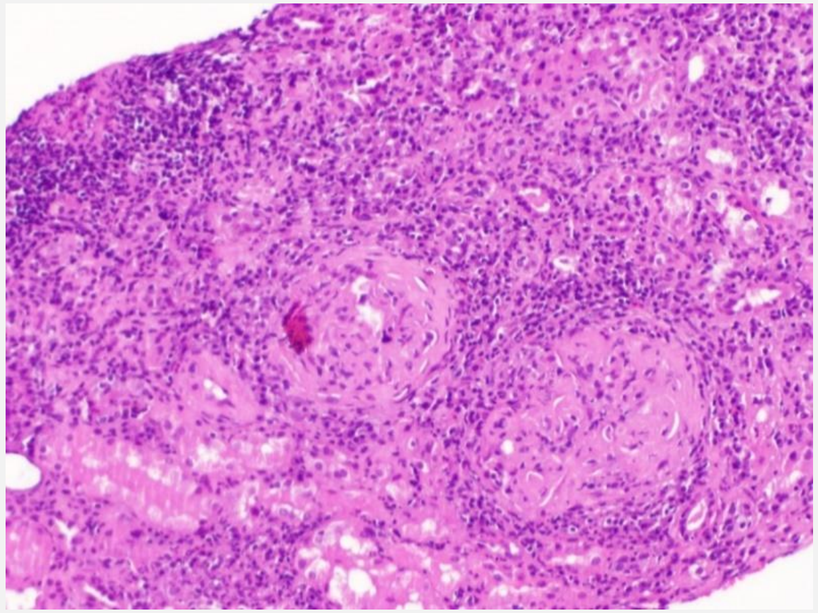

B

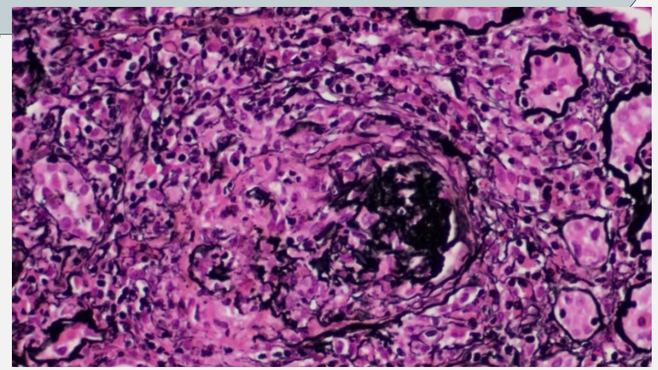

C

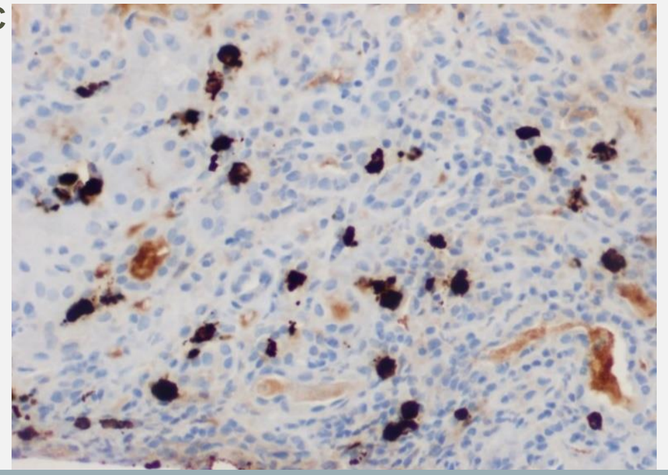

Figure 1: A – H&E, 20x severe interstitial lymphoplasmacytic infiltrate; B - silver stain, 40x glomerulus with a cellular crescent; C – IgG 4 immunohistochemistry, 40x IgG4 positive plasmocytes

83-year-old with past history of
ry tuberculosis and hypertension.
Presented with:

, weight loss and fatigue in the last 6 months:

At admission, the
The blood tests

→ Rapidl
(sCr 4.1

→ Sever
systemi
respons

→ Urine
proteinu
sedimen
leukocytu

→ Immu
serum I
elevated
myeloper
(66U/mL

On light microscopy kidney biopsy showed a **severe interstitial lymphoplasmacytic infiltrate and cellular crescentic lesions (5/8).** Immunofluorescence was negative. Immunohistochemical study showed **more than 30 IgG4 positive plasmocytes** per large magnification field.

Crescentic pauci-immune glomerulonephritis (GN) and IgG4 interstitial infiltrate

The patient started **corticotherapy** (pulses of 500mg/day of methylprednisolone, then oral prednisolone, 1mg/Kg/day) as well as 375/m^2 **rituximab** with

A B C

In the last decade, an increasing number of case reports were described with a **simultaneous diagnosis of AAV and IgG4-RD**. Some have histopathologic confirmation of both; however, the majority have IgG4-RD with ANCA positivity or diagnosis of AAV with increased IgG4-positive plasma cells, raising the possibility of an ***overlap syndrome***.

The presence of **elevated IgG4** as well as **IgG4-positive plasma cell infiltration is not specific of IgG4-RD** and is frequently seen in **AVV**. Plasma cell-rich AAV (> 45% of plasma cells in the kidney infiltrate) is not rare.

Could IgG4 have a role on the pathogenesis of AVV and be related to disease activity?

The **distinction of these is essential** in terms of treatment and prognosis. It is important **not to overdiagnosis** IgG4-RD. Interestingly, the cases described with the two diseases, all involved high immunosuppression.

This suggest that the **treatment of AVV should be the priority**, independently of criteria of IgG4-RD.

Nephro Update Europe 2020
18 – 19 September, Amsterdam (Noordwijk)

KIDNEY DISEASE

Proteinase 3 (PR3) – antineutrophil cytoplasmic antibody in minimal change disease: an unusual finding

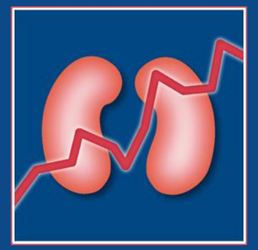

Joana Freitas, Portugal

Proteinase 3 (PR3) – antineutrophil cytoplasmic antibody in minimal change disease: an unusual finding

Freitas, J; Sala, I; Oliveira, JP; Tavares, JM; Silva, F; Santos, S; Campos, A; Santos, J; Cabrita, A

Nephrology Department, Centro Hospitalar Universitário do Porto

Introduction

Antineutrophil cytoplasmic antibodies (ANCA) has utility as a marker of systemic vasculitis. Proteinase 3(PR3)-ANCA antibodies has been also identified in chronic inflammatory, infectious non-vasculitic conditions and in association with drugs. The association of PR3 and minimal change disease without vasculitis is not an usual finding. We report a patient with biopsy-documented minimal change nephropathy associated with high PR3-ANCA title.

Case Description

- ♀, 86-years-old, without relevant past pathological history and normal renal function
- A month before admission, presented with bilateral ankle swelling and progressive dyspnea.
- On admission, she was hypertensive and serum analysis showed rapidly progressive renal failure (**serum creatinine(sCr) 4,37mg/dL, hypoalbuminemia 1,77mg/dL**).
- She had a **19 g/g protein/creatinine ratio**.
- Renal ultrasound was normal.
- Auto-immune screening revealed PR3-ANCA positive (**238,7UQ**) but absent perinuclear ANCA.
- Renal biopsy did not show any features of vasculitis or crescentic glomerulonephritis. The glomeruli showed only discret mesangioproliferative features and the immunofluorescence had no glomeruli.

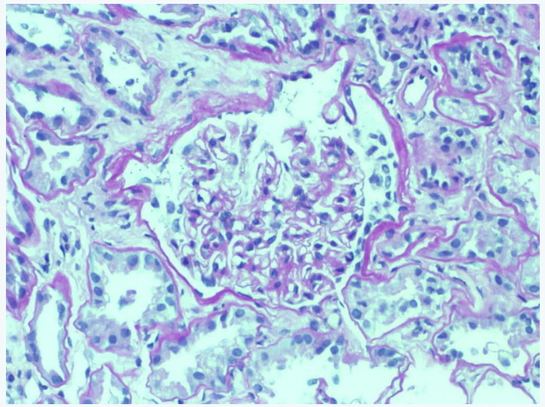

Normal glomeruli in optic microscopy; PAS, 20x

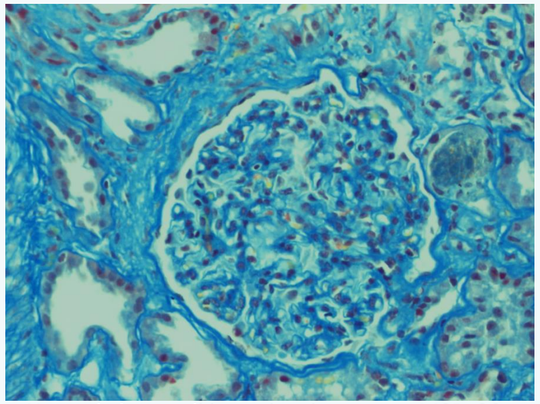

Normal glomeruli in optic microscopy; MSB, 20x

Discussion

- Minimal change disease was assumed and she started corticotherapy (pulses of methylprednisolone, then oral Prednisolona 1mg/Kg) with clinical and analytical improvement (**sCr 1,70mg/dL, protein/creatinine ratio 3,6g/g; PR3 107UQ**), a month after treatment.
- Auto-immune, inflammatory and infectious diseases were excluded.

- ANCA-associated glomerular disease has also been described to coexist with a variety of other glomerular diseases including membranous nephropathy, lupus nephritis, IgA nephropaty and bacterial infection-related glomerulonephritis.
- Our finding may represent an incidental association or be related with two distinct diseases entities or even other disease.

Conclusion

In our case, the initial presentation tended to assume GPA with positive PR3 antibody but renal biopsy had no features of vasculitis or crescentic glomerulonephritis. This association has not been reported before, to our best knowledge.

Therefore, our case emphasizes the importance of performing renal biopsies before embarking on a full-scale immunosuppression therapy based in ANCA title alone, especially in patients with nephrotic syndrome without clinical features of vasculitis, as this would lead to significant change in management.